

Modernizing breast cancer rehabilitation

Clinical best practices for lymphedema assessment and referral pathways



Tactile
MEDICAL®



This course was designed by
Tactile Medical for Select Medical[®]
therapists trained in the ReVital[™]
cancer rehabilitation program


Tactile
MEDICAL[®]

Tactile Medical at a glance

Our Mission:

To reveal and treat patients with underserved chronic conditions and help them care for themselves at home

FOUNDED	1995
HEADQUARTERS	Minneapolis
TOTAL EMPLOYEES	~1,100
PATIENTS SERVED IN 2025	>97,000
PRODUCTS	Flexitouch® Plus, Nimbl™, Kylee™, AffloVest®



Clinical experts



Dr. Michael Stubblefield

Cancer Rehabilitation Medical Director, Kessler Institute for Rehabilitation

National Medical Director, Select Medical, ReVital Cancer Rehabilitation program

Clinical Professor, Department of PM&R, Rutgers University, New Jersey Medical School



Mary Calys, DPT, CLT, FDNS, TPS

Senior Clinical Specialist, Tactile Medical

Norton School of Lymphatic Training

Cancer Exercise Specialist, Rocky Mountain Cancer Rehab Institute

Functional Dry Needling Specialist, Therapeutic Pain Specialist, Purdue



Helen Laktas, OTR/L, CLT, MBA

Oncology Key Account Manager, Tactile Medical

Norton School of Lymphatic Training

Klose Breast Cancer Rehab Training

PORi Cancer Rehab Training

Lymphatic Education and Research Network

Missouri Board Co-Chair

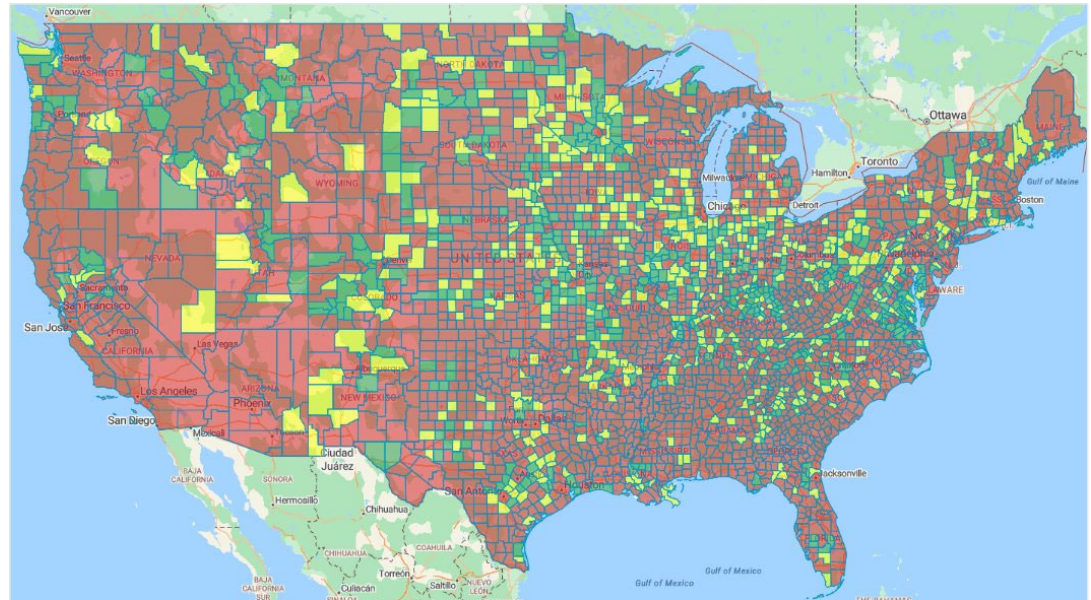
Cancer rehab paradigm shift



Lymphedema access to care: Urgent

US population: 340 million

- Lymph population: 921,984
- # of CLTs: 8,514
- # of lymph pts per CLTs: 108
- Ave appoint time: 1 hour
- Ave wait post dx: >8 months



United States	
County:	Estimated LE Population (921,984) to Clinician (8,514) Ratio
	<=3 Estimated LE Patients per Clinician
	4-7 Estimated LE Patients per Clinician
	>=8 Estimated LE Patients per Clinician

CLT Data Source: Klose, Vodder, ACOLS, and TCMD Training Demographics.
Estimated Lymphedema Prevalence: 3 in 1000 (per 2015 study Estimating the Prevalence of Lymphedema in the United States by Julie Hanson MD, FAAP, CLT-LANA)

Green: Sufficient CLT coverage
 Red: Do not have ready access

Objectives

- Accurately identify risk factors, early signs and symptoms of cancer-related lymphedema in breast cancer survivors.
- Implement early treatment interventions to limit progression to late-stage lymphedema and to manage lymphedema caseloads and fiscal considerations effectively.
- Apply “screen, stage, recommend” decision process in clinical practice through case study review.
- Access resources and decision tools to support evidence-based recommendations and national survivorship guidelines.
- Collaborate effectively with interdisciplinary cancer care teams to optimize patient outcomes and ensure continuity of lymphedema management across care settings.

Breast cancer treatment evolution

Breast cancer surgical evolution

Breast surgery practices are less invasive in late 20th century

1970s: Lumpectomy + radiation because viable vs. radical mastectomy

1990s: Introduction of SLNB reduced the need for full ALND

2000s: Advances in oncoplastic surgery and nipple-sparing mastectomies for improved cosmesis and function. Patients expect to look and feel good.

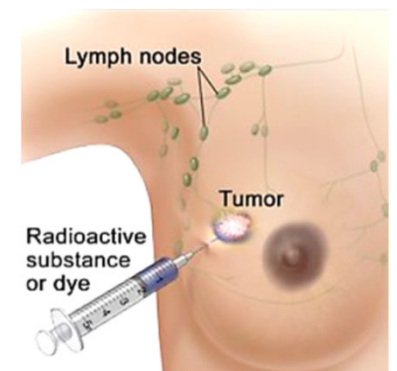
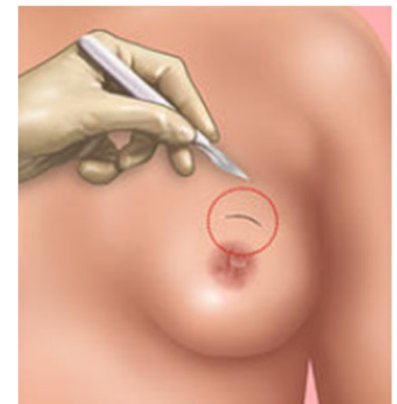
Gold standard treatment

Lumpectomy + radiation therapy
Supporting guidelines:
NCCN, ASCO, ESMO



Common result

Breast & trunk
lymphedema



Sentinel lymph node biopsy (SLNB)

Sentinel lymph node: first lymph node(s) that receives lymphatic drainage from the primary tumor

SLNB is performed to determine if cancer has spread from the tumor to nearby lymph nodes

1. Radioactive substance and/or blue dye injected near tumor
2. First lymph node(s) that receive the substance are removed
3. Pathologist views the lymph node(s) looking for cancer cells

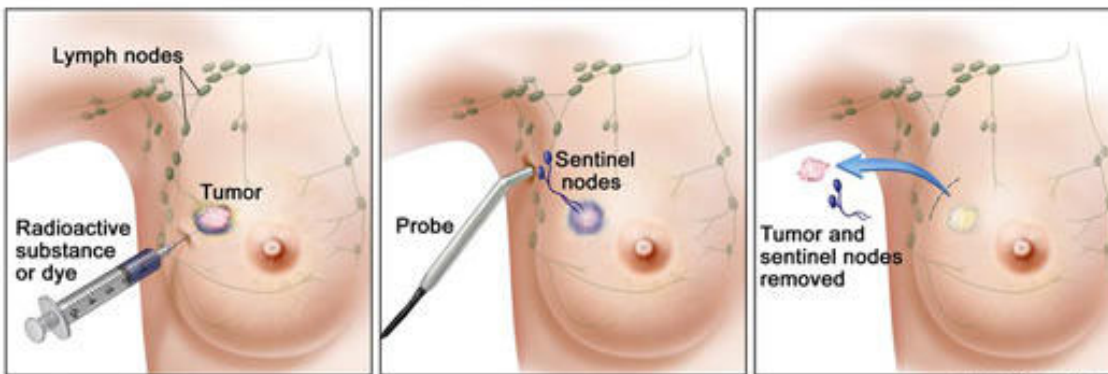
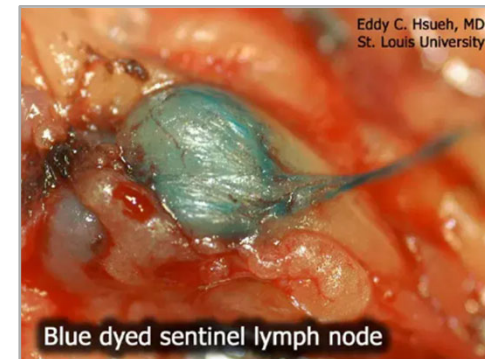


Photo credit: National Cancer Institute

© 2010 Terese Winslow
U.S. Govt. has certain rights



Eddy C. Hsueh, MD
St. Louis University

https://www.researchgate.net/publication/6351595_Axillary_Reverse_Ma...

Axillary lymph node dissection (ALND)

~10 lymph nodes removed and evaluated for accurate axilla staging

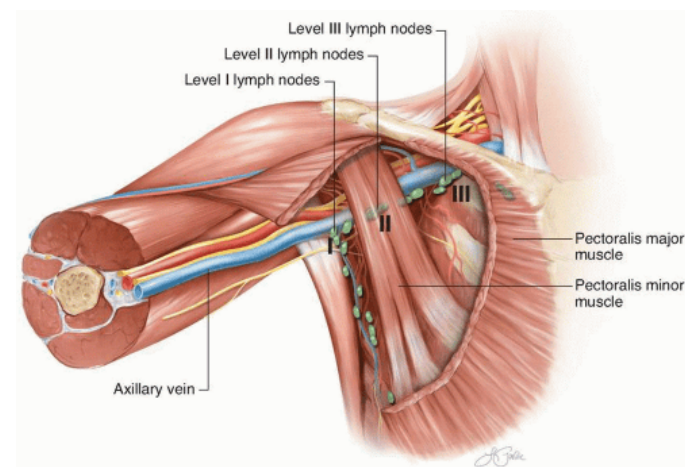
Typically, level I and II lymph nodes are removed

- Level I: inferior/lateral to pec minor
- Level II: deep to pec minor
- Level III: superior/medial pec minor

Anatomical region removed with surgical borders of

- Superior: Axillary vein
- Lateral: Latissimus dorsi muscle
- Medial: Medial border of pectoralis minor muscle

Usually performed during mastectomy or breast-conserving surgery (lumpectomy)



Treatment implications: SLNB vs. ALND

Sentinel lymph node biopsy (SLNB)

- No drains involved
- Less scarring
- Faster recovery
- Reduced lymphedema

Axillary lymph node dissection (ALND)

- Upper extremity morbidity
- More pain
- Seroma
- Axillary webbing/cording
- Paresthesia
- Increased lymphedema risk

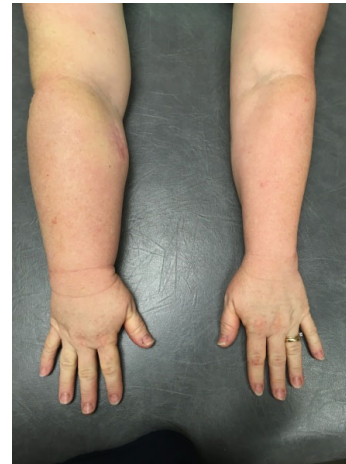

Photo Credit: Encore Rehabilitation, Inc.

Arm lymphedema

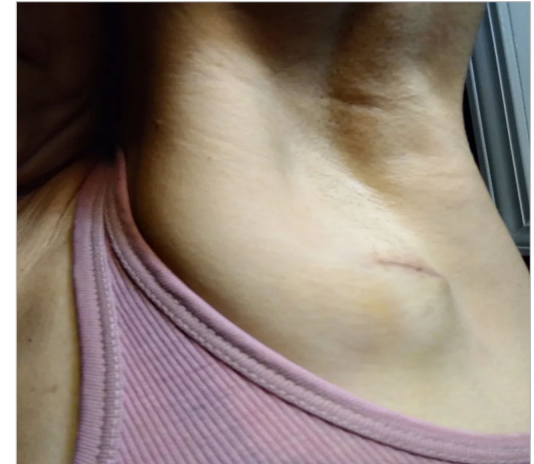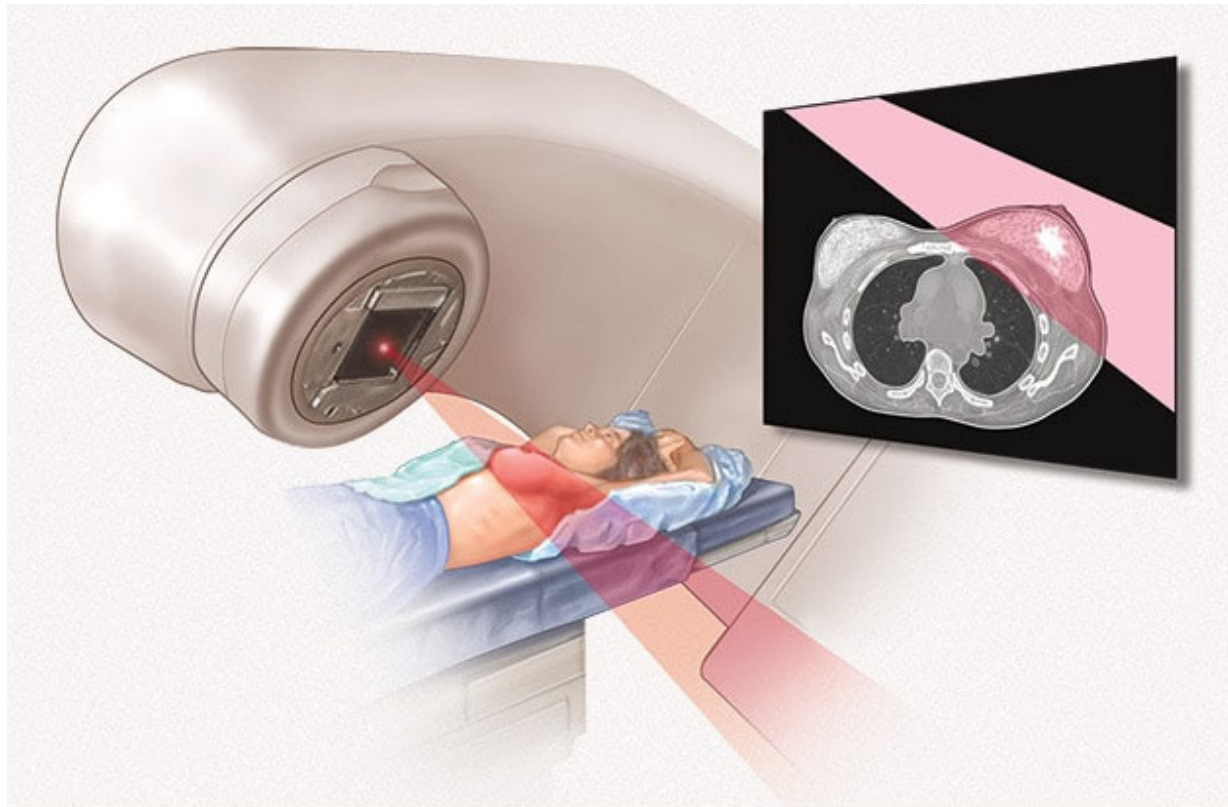


Photo Credit: Tamara Adams

Seroma

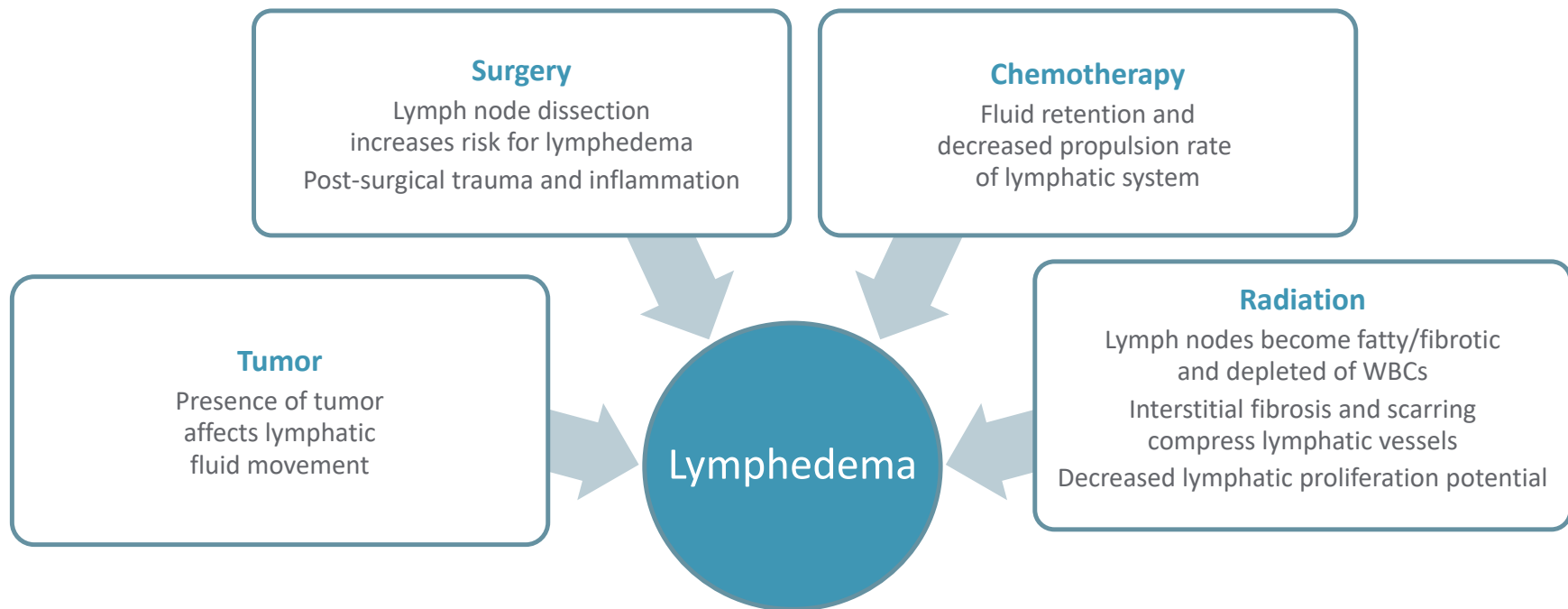
Higher rate of lymphedema after ALND compared to SLNB, although other risk factors play a role

External beam radiation to the breast



© MAYO FOUNDATION FOR MEDICAL EDUCATION AND RESEARCH. ALL RIGHTS RESERVED.

Cancer affects the lymphatic system in multiple ways



Ridner SH, Dietrich MS, Niermann K, Cmelak A, Mannion K, Murphy B. A Prospective Study of the Lymphedema and Fibrosis Continuum in Patients with Head and Neck Cancer. *Lymphat Res Biol.* 2016 Dec;14(4):198-205.

Chaput G, Ibrahim M, Towers A. Cancer-related lymphedema: clinical pearls for providers. *Curr Oncol.* 2020;27(6):336-340.

Allam, O. et al. The impact of radiation on lymphedema: a review of the literature. Division of Plastic and Reconstructive Surgery, Yale University, New Haven, CT, USA. Dec 24, 2019

Johnson AR, Granoff MD, Lee BT, Padera TP, Bouta EM, Singhal D. The Impact of Taxane-based Chemotherapy on the Lymphatic System. *Ann Plast Surg.* 2019;82(4S Suppl 3):S173-S178. doi:10.1097/SAP.0000000000001884

Lee KT, Mun GH, Lim SY, Pyon JK, Oh KS, Bang SI. The impact of immediate breast reconstruction on post-mastectomy lymphedema in patients undergoing modified radical mastectomy. *Breast.* 2013 Feb;22(1):53-7.

Miller CL, Colwell AS, Horick N, Skolny MN, Jammallo LS, O'Toole JA, Shenouda MN, Sadek BT, Swaroop MN, Ferguson CM, Smith BL, Specht MC, Taghian AG. Immediate Implant Reconstruction Is Associated With a Reduced Risk of Lymphedema

Compared to Mastectomy Alone: A Prospective Cohort Study. *Ann Surg.* 2016 Feb;263(2):399-405.

Lymphatic anatomy and physiology

What is the lymphatic system?

Lymphatic vessels: Span the entire body, lymph fluid travels throughout

Lymph nodes: 600-800 throughout the body. Filter lymph fluid including toxins/bacteria.

Lymph fluid: Clear to white fluid composed of

- Protein
- Fat
- Water
- Waste products (cellular debris)

Lymphoid tissue: Important to immune system by producing/storing white blood cells

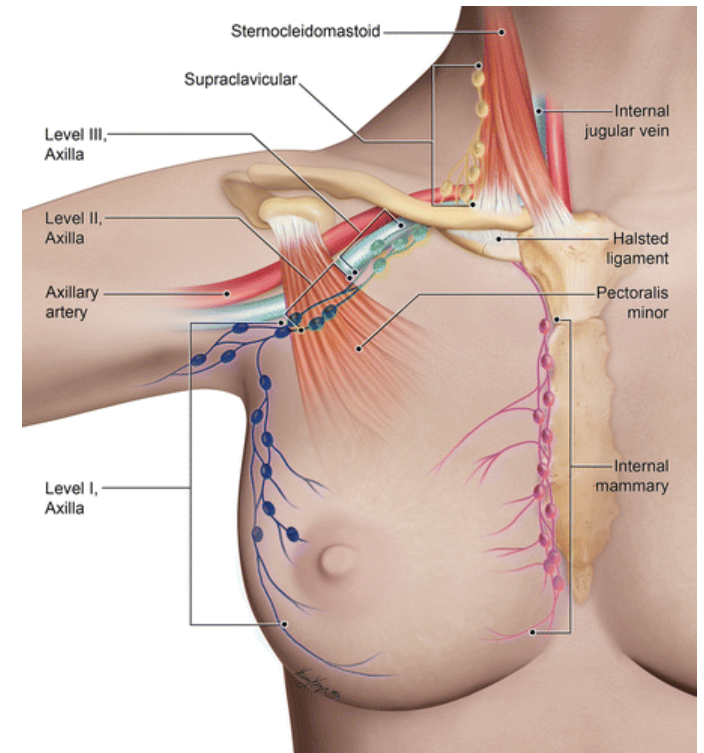
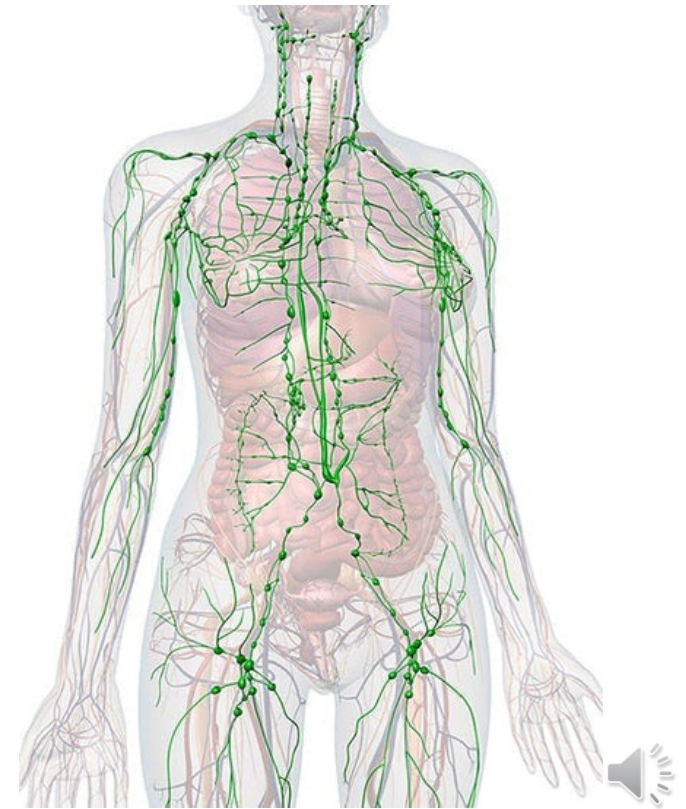


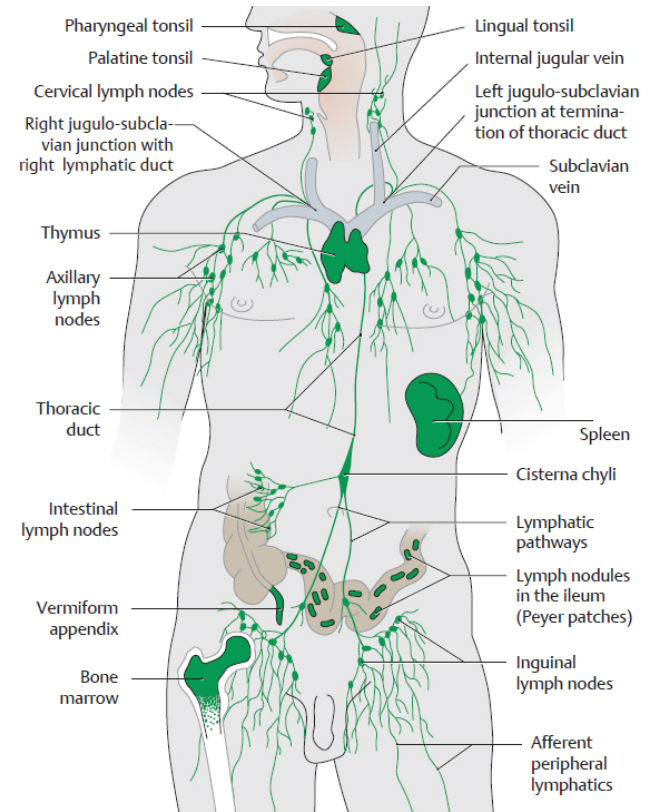
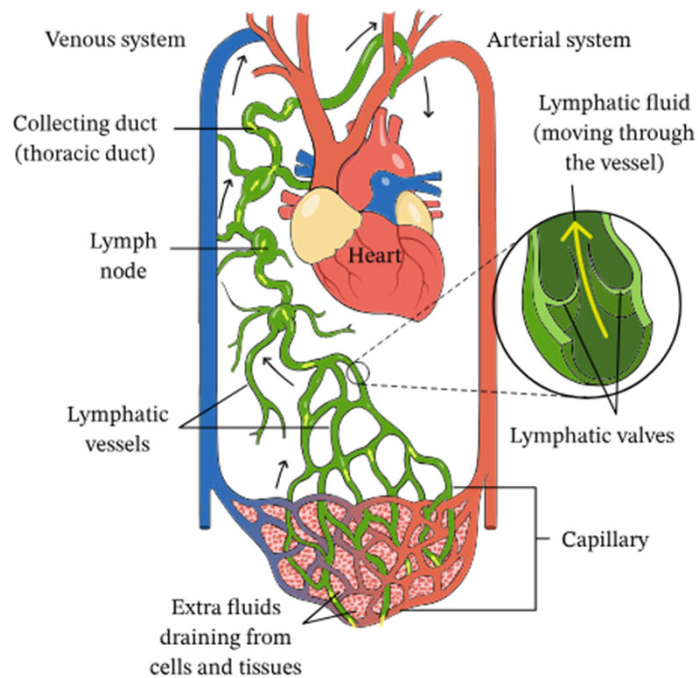
Photo Credit: Chung et al (2021)

Functions of the lymphatic system

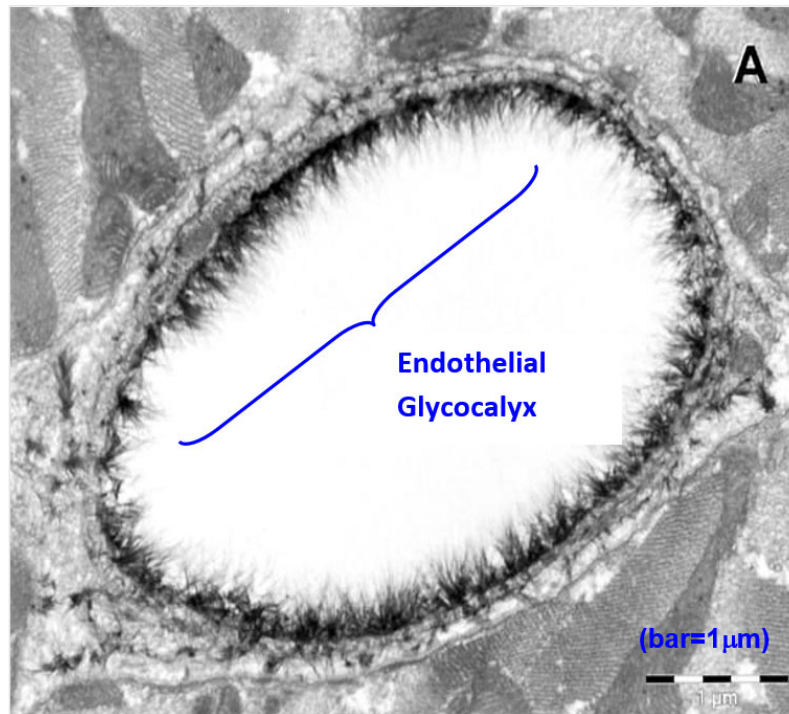
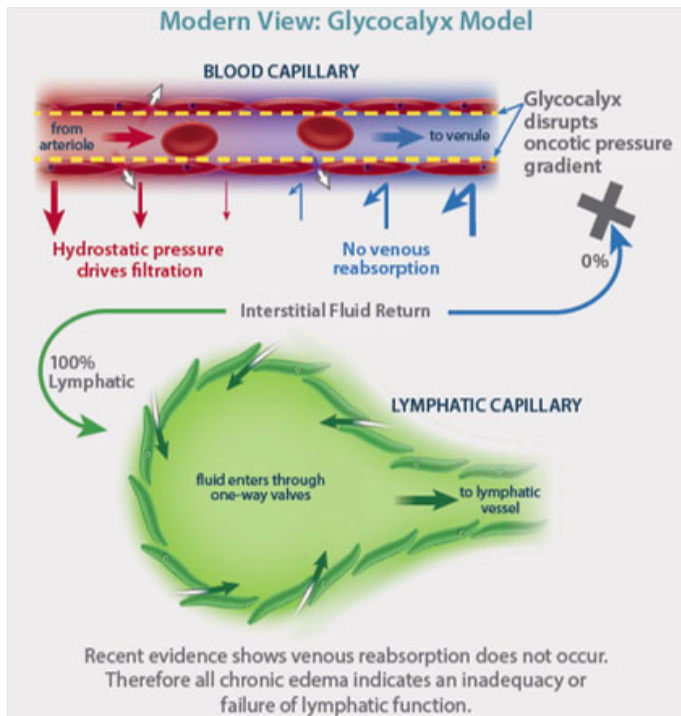
- The lymphatic system is an "open" drainage system
- Removes excess fluid from the body tissues and returns it to the blood stream
- Absorbs fatty acids and fats from the digestive system
- Transports white blood cells to and from the lymph nodes into the bones
- Transports antigen presenting cells, such as dendrite cells to the lymph nodes where an immune o is stimulated



Components of the lymphatic system




Microcirculation and the endothelial glycocalyx



Chappell D et al. Cardiovasc Res 2009; 88:388-96

The presence of chronic edema is always indicative of a failure of the lymphatic system to manage this fluid, thus all chronic edema is lymphedema

Lymphatic capillaries and collectors



Lymphatic trunks and ducts

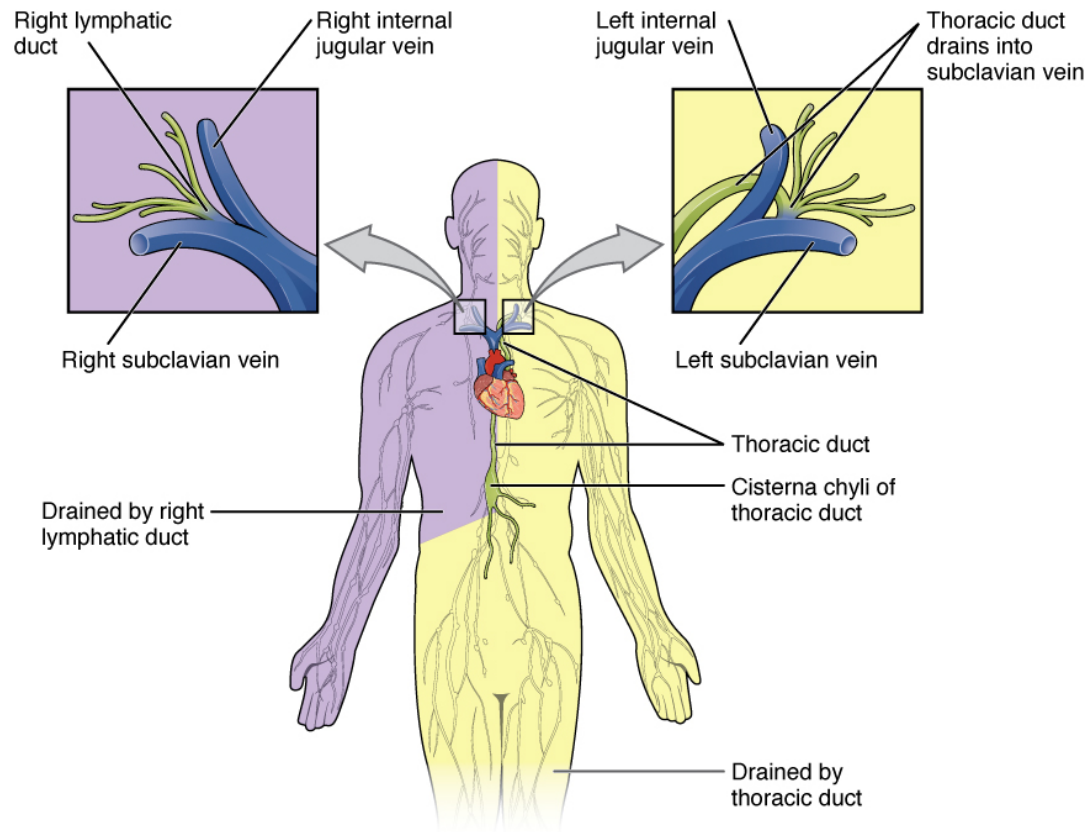
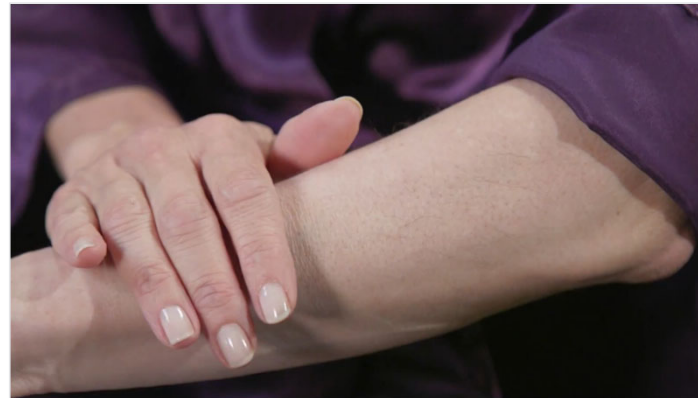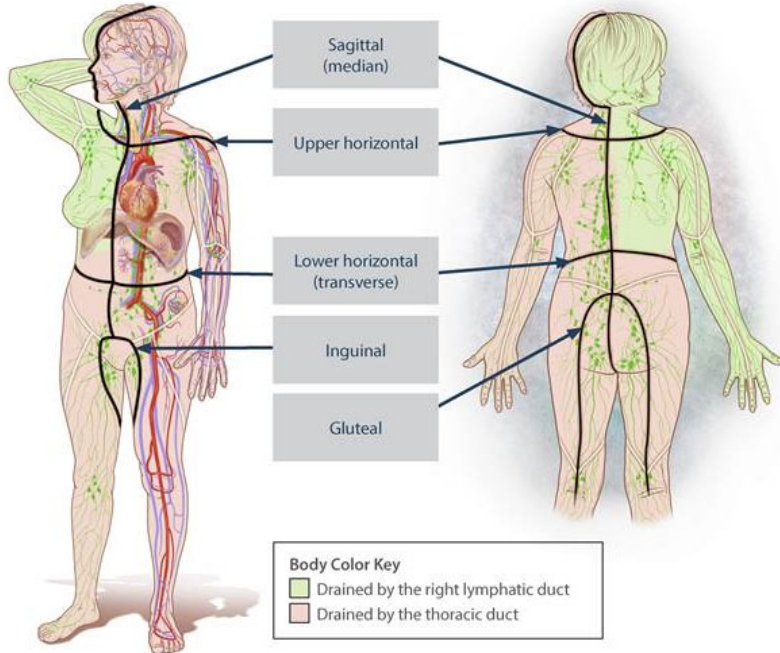


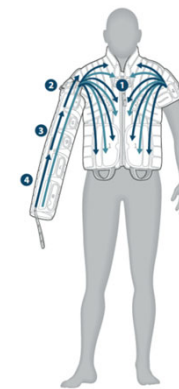
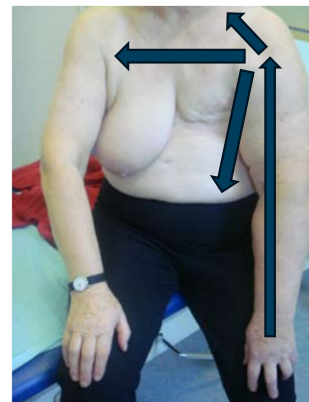
Photo credit: Illustration from Anatomy & Physiology, Connexions Web site. Jun 19, 2013.

Lymphatic watersheds

Represent linear areas on the skin that separate drainage areas of the lymphatic system



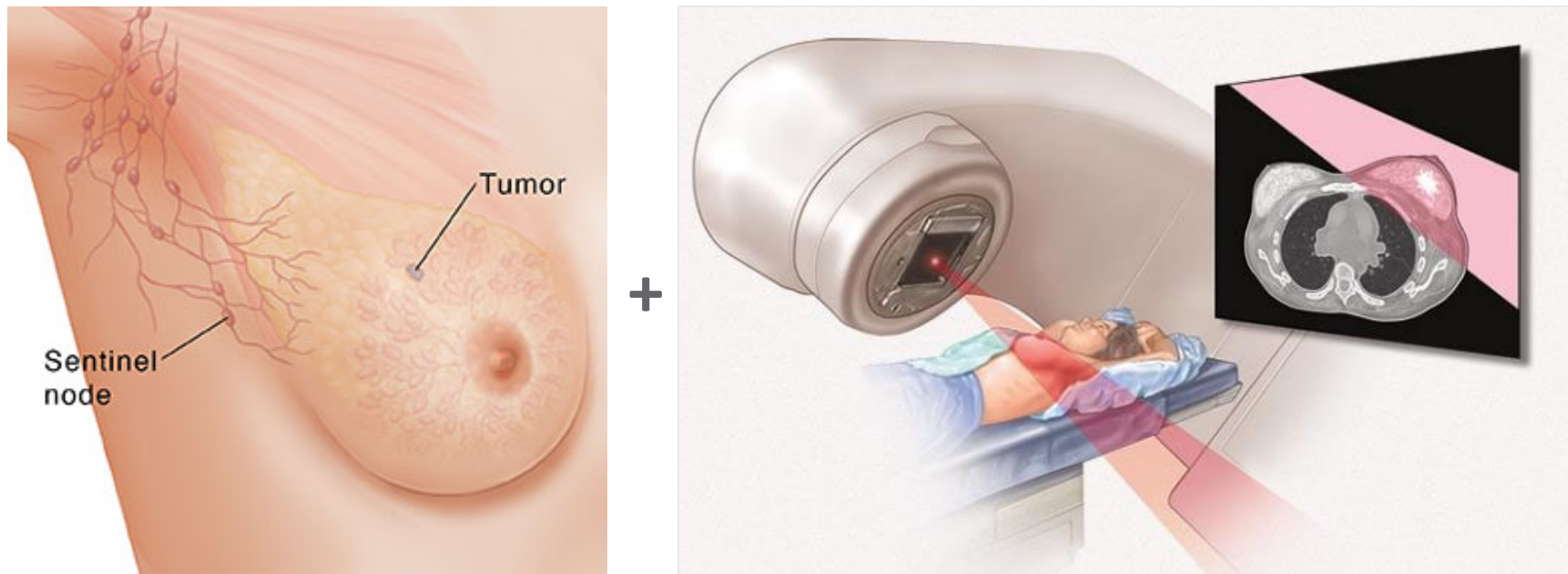
Video credit: MD Anderson Cancer Center - <https://www.youtube.com/watch?v=qmebH1c4qU>



Breast cancer related-lymphedema and radiation fibrosis syndrome

Breast and truncal lymphedema incidence

Current research shows breast and truncal lymphedema occurs in 40-65% of patients



Lumpectomy and external beam radiation can cause **fibrosis, scarring, tightness and cording**:
These are all symptoms correlated with lymphedema

Lymphedema stages and progression

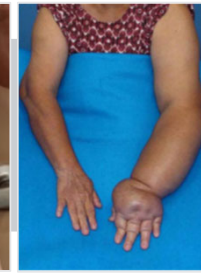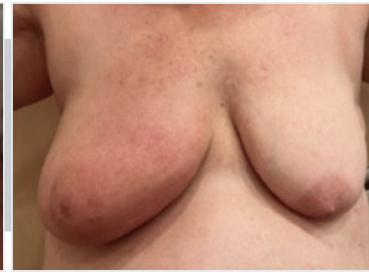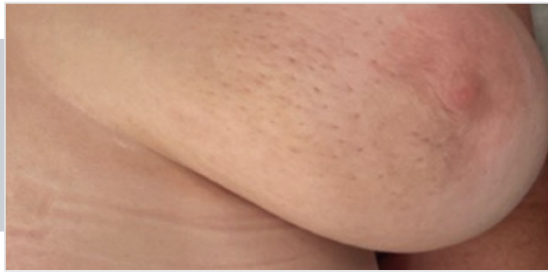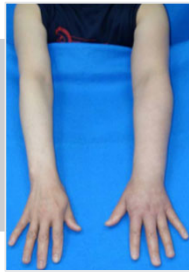Stage 0: Latent/subclinical

No evident swelling
Impaired lymphatic transport
results in symptoms – heaviness,
tightness, discomfort, etc.

Stage 2: Irreversible

Swelling evident and does not fully
resolve with elevation
Fibrosis develops
Pitting is evident initially but eventually
prevented by fibroadipose tissue

Symptoms,
no overt
edema



Stage 1: Reversible

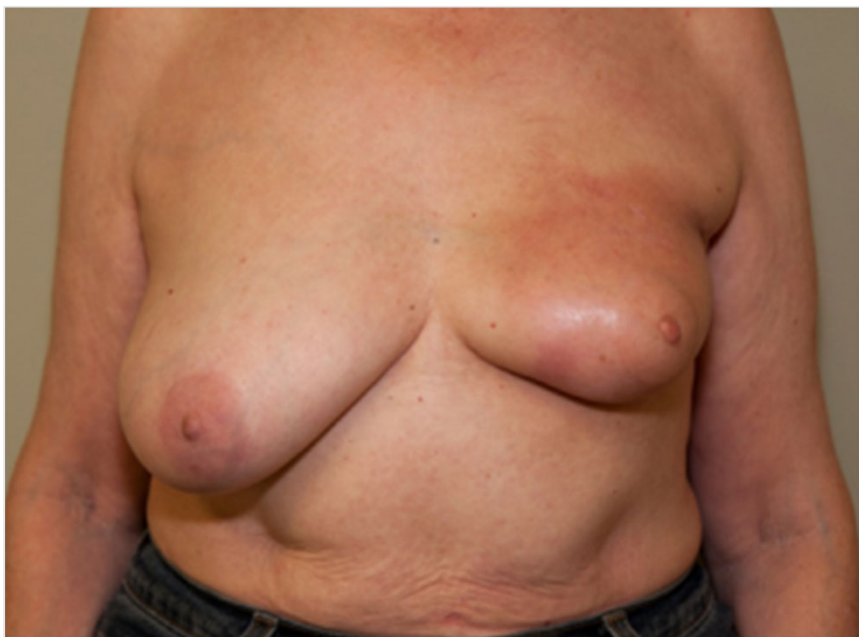Early accumulation of high
protein fluid
Pitting may occur
Swelling intermittent or subsides
with elevation

Stage 3: Late stage

Further skin changes
may include increased
skin thickness, further
fat deposition, fibrosis,
and warty overgrowths

Treat to highest stage present

Fibrosis, stage II lymphedema left breast



Stubblefield MD. Radiation fibrosis syndrome: neuromuscular and musculoskeletal complications in cancer survivors. PM R 2011;3(11):1041-54.

Assessment and staging

Patient report: pain, tenderness, tightness in L breast, no complains L UE

Palpation: L breast skin thickening, fibrosis, adhesion at surgical site

Range of motion: Slight limitation L shoulder flexion

Photograph: L breast induration, radiation fibrosis, volumetric reduction, breast tissue contraction

Measurement: no measurable swelling in L arm or breast

Staging: Stage II lymphedema in L breast, Stage 0 L arm

Slide 26

HL1 [@Mary Calys] can you review this content and let me know if you have any recommendations? Key message is that the breast/ chest can be stage II while arm is stage 0

Helen Laktas, 2026-03-12T14:41:03.359

MC1 0 ROM deficits in the L shoulder may or may not be present.

Mary Calys, 2026-03-12T15:48:03.428

NCCN clinical practice guidelines in oncology (NCCN buidelines): Survivorship

Version 2.2025: May 23, 2025

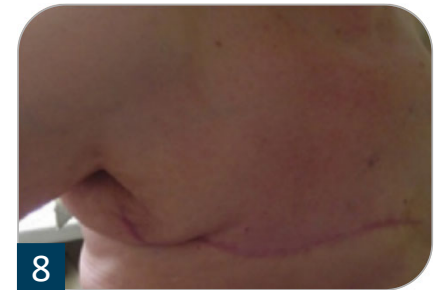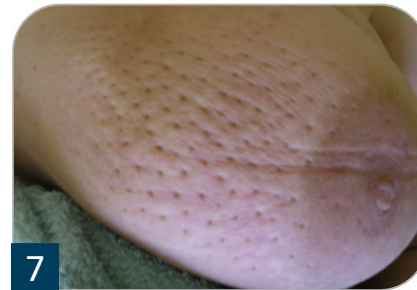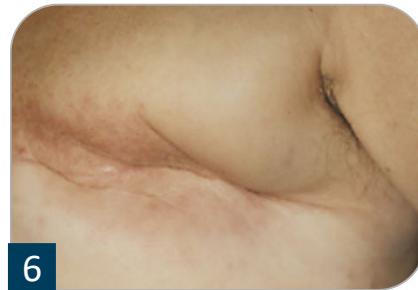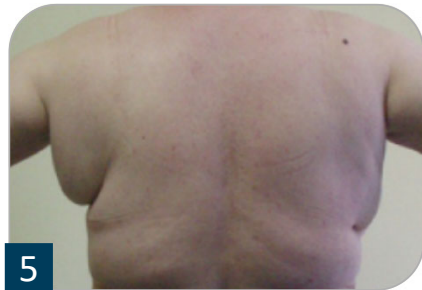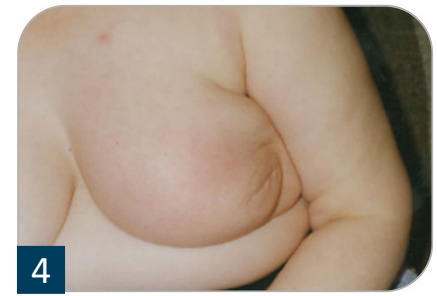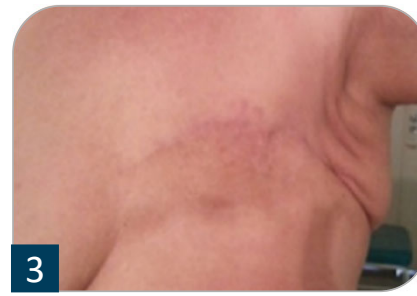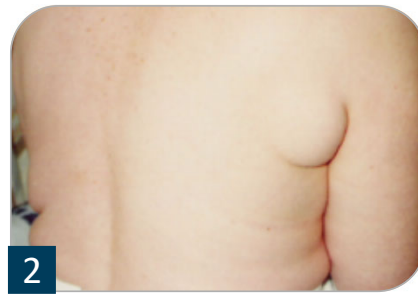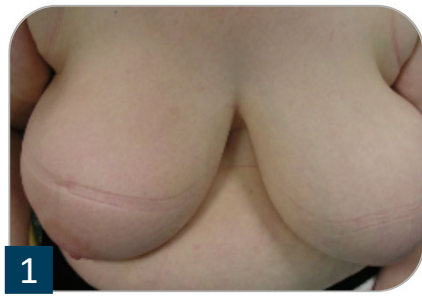Early detection/diagnosis and early referral are key for optimal lymphedema management because stages 0 and 1 are reversible, whereas stages 2 and 3 are less responsive to treatment. Therefore, survivors at risk for lymphedema should be regularly screened for lymphedema by symptom assessment and clinical exam.

Survivors should be educated regarding

- Early signs and symptoms of lymphedema including fullness, tightness, heaviness, and pain, and the importance of rapid reporting to the treatment team.
- Self-care management including compression garments, manual lymphatic drainage, and pneumatic compression for ongoing home management.

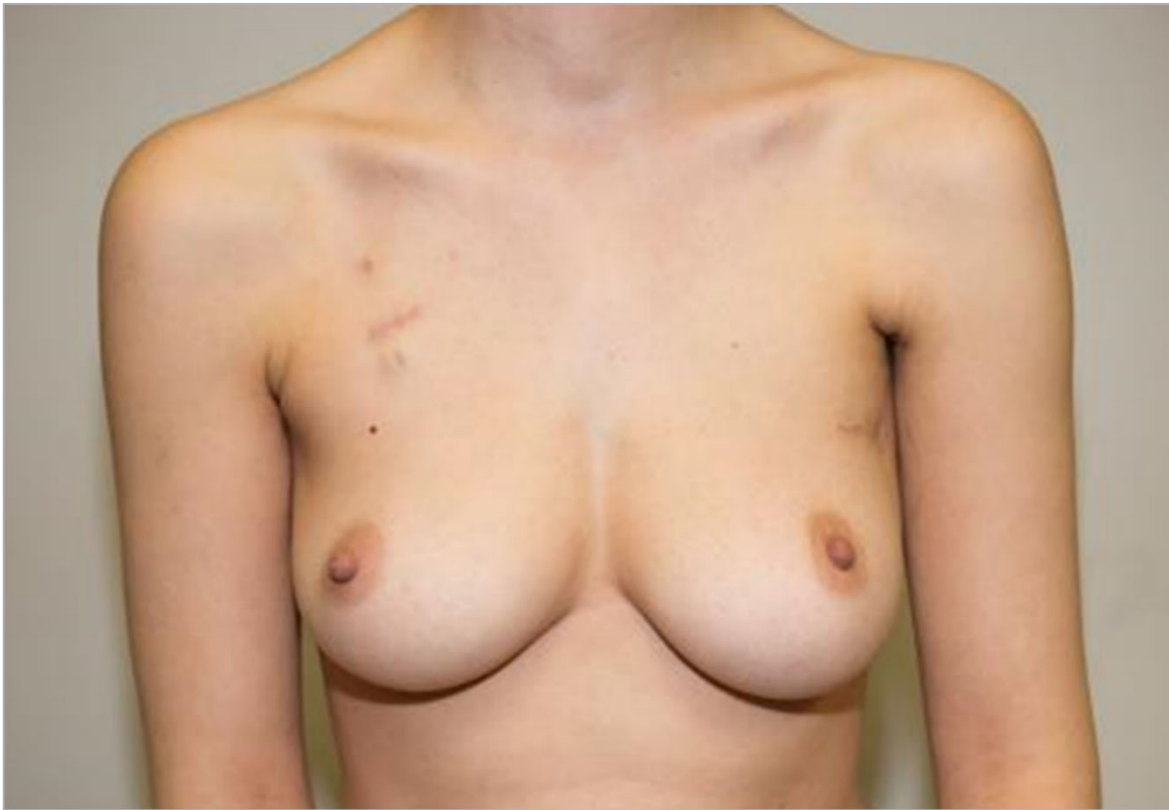

Clinical presentation of breast and trunk lymphedema



No two patients will present the same. Observe for unique characteristics to identify lymphedema and fibrotic skin changes.

Mild clinical presentation of BCRL



Trunk symptoms

Note: Differences in bra fit, including indentation at bands/straps or changes in band and cup size, are common indicators of truncal swelling.

Breast, chest and collarbone area:

- Swelling or puffiness
- Heaviness or fullness
- Tightness or firmness
- Dimpled hair follicles on breast; orange peel appearance

Side and axilla (armpit):

- Swelling or puffiness
- Heaviness or fullness
- Tightness or firmness
- Feeling of a "ball" preventing arm from resting at side
- Feeling of a cord pulling with motion

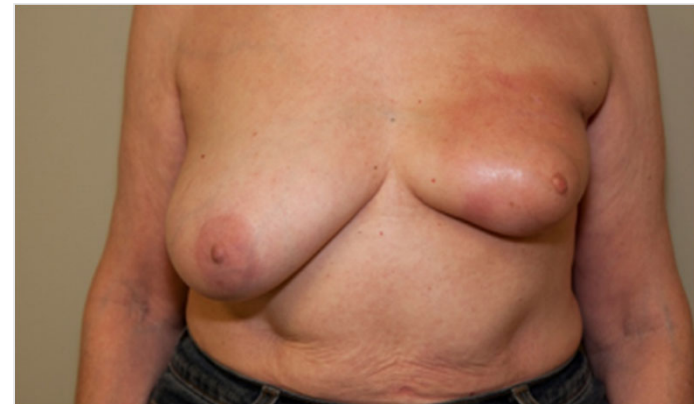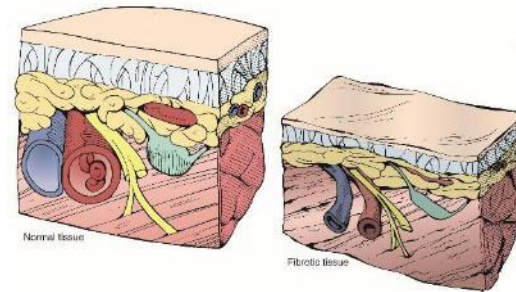
Shoulder and back:

- Swelling or puffiness
- Heaviness or fullness
- Tightness or firmness
- Limited range of motion
- Pain

Radiation fibrosis syndrome

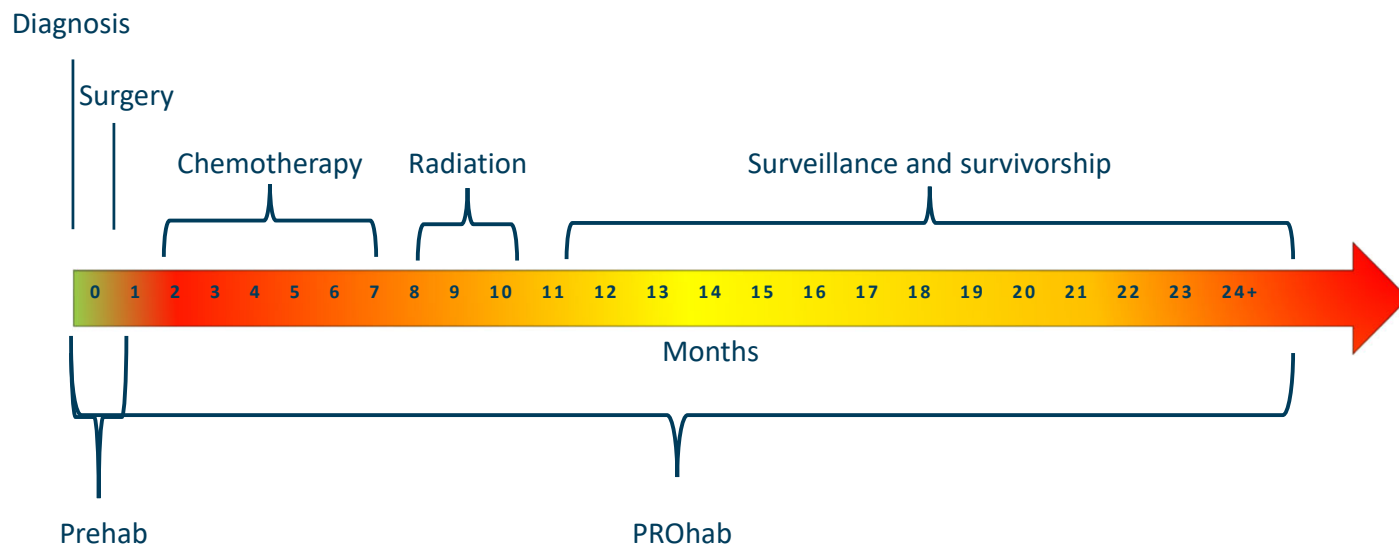
“Radiation fibrosis (RF) describes the insidious pathologic fibrotic tissue sclerosis that often occurs in response to radiation exposure.”

“The term radiation fibrosis syndrome (RFS) describes the myriad clinical manifestations of progressive fibrotic tissue sclerosis that result from radiation treatment.”



Stubblefield MD. Radiation fibrosis syndrome: neuromuscular and musculoskeletal complications in cancer survivors. *PM R* 2011;3(11):1041-54.

Progression of lymphedema and fibrosis



Pathogenesis of lymphatics to fibrosis anatomic changes

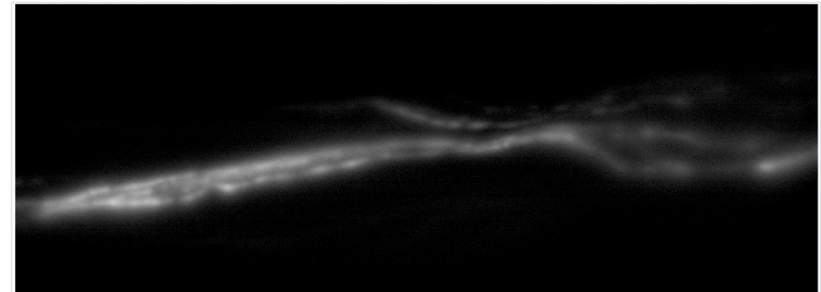
Stage 0

- Well-defined linear collecting lymphatic vessels
- Aching, heaviness, “strange feeling”

Stage 1

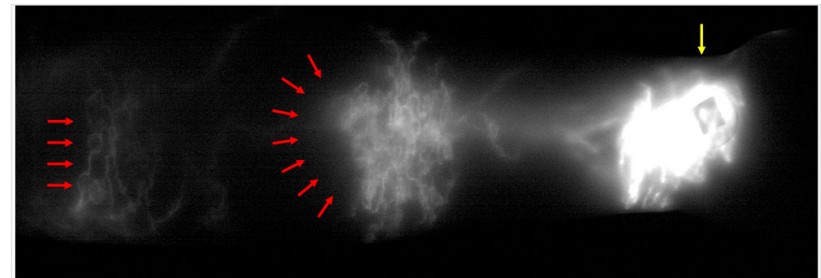
- Dilated lymphatics with irregular pulsation
- Localized areas of dermal back flow
- Formation of hyperplastic, irregularly shaped lymphatic vessels

Stage 0



Copyright © 2024 Wolters Kluwer. Published by Lippincott Williams & Wilkins

Stage 1



Copyright © 2024 Wolters Kluwer. Published by Lippincott Williams & Wilkins

Pathogenesis of lymphatics to fibrosis anatomic changes

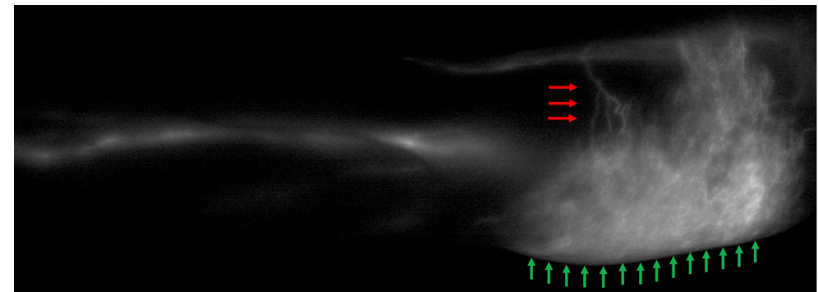
Stage 2

- Proliferation and accumulation of adipocytes due to exposure to fatty acids in lymphatic fluid
- Loss of major collectors
- ↑ back flow
- ↓ lymphatic pumping
- Hyperplastic collectors

Stage 3


- Diffuse dermal back flow
- No recognizable patent collecting vessels

Stage 2



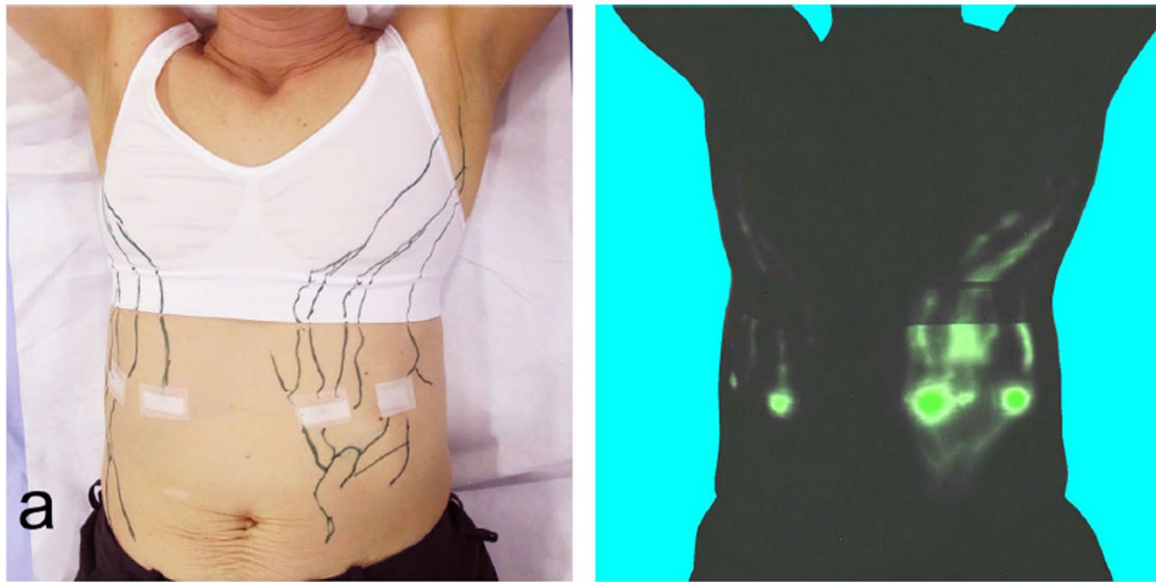
Copyright © 2024 Wolters Kluwer. Published by Lippincott Williams & Wilkins

Stage 3



Copyright © 2024 Wolters Kluwer. Published by Lippincott Williams & Wilkins

ICG highlights dermal backflow in breast lymphedema



Control group demonstrates normal lymphatic flow without dermal backflow present
100% of controls had drainage to ipsilateral axilla

ICG highlights dermal backflow in breast lymphedema

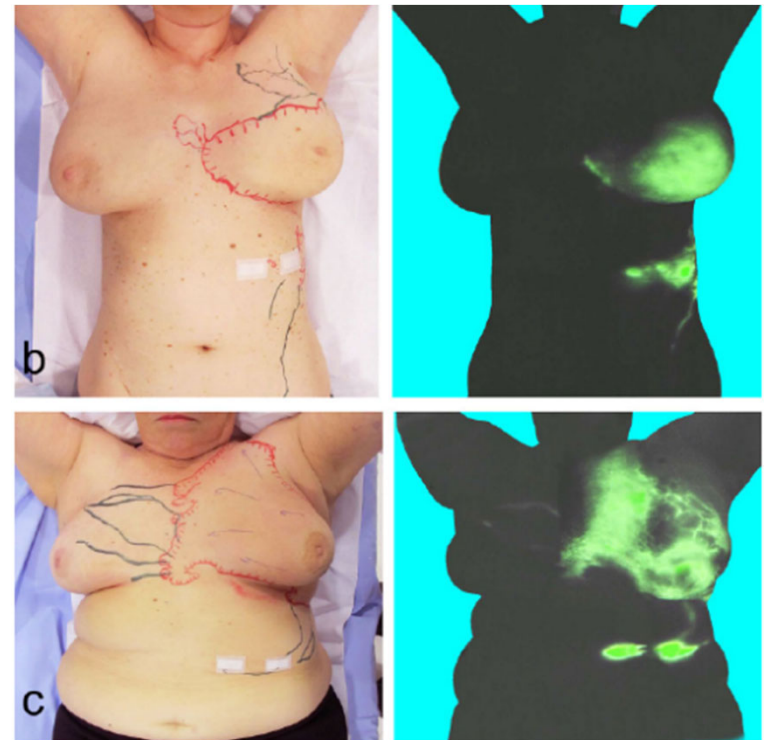
100% of patients with breast lymphedema had dermal back flow

100% had elevated TDC ratios compared to controls

80% had fibrosis

Self reported symptoms

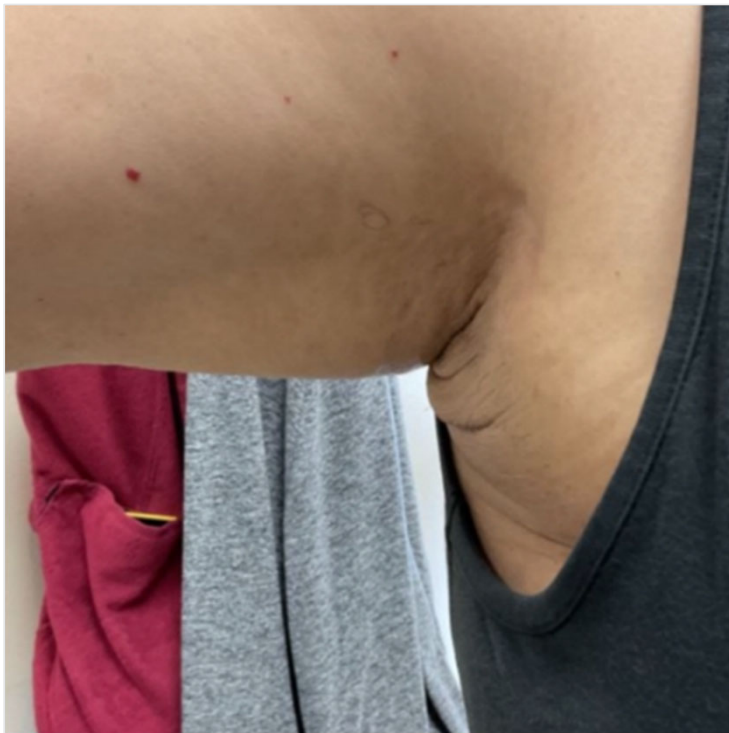- **100%:** Swelling
- **70%:** Heaviness
- **70%:** Discomfort



Assessment of the breast and trunk

Identification and assessment methods

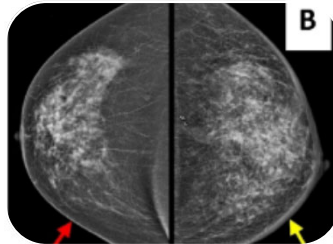
Patient presentation



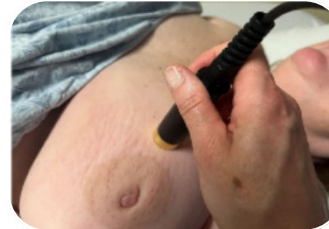
Traditional measurements



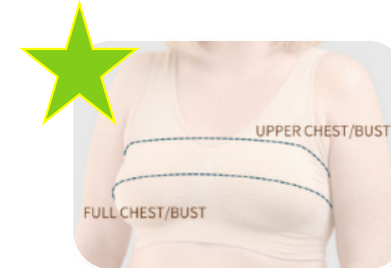Assessment of the breast and trunk



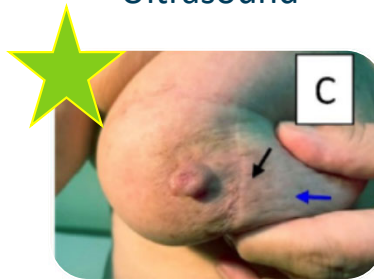
Ultrasound



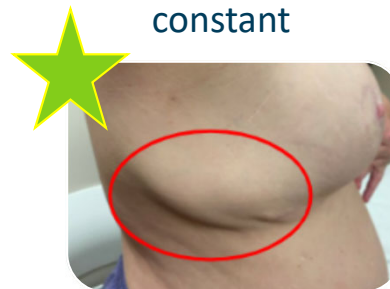Tissue dielectric constant




Girth measurements



Tissue palpation and visual assessment



Photos



Lymphedema questionnaires

Photo credit: ultrasound, TDC, and palpation: Brunelle CL, Boyages J, Jung AW, et al. Breast lymphedema following breast-conserving treatment for breast cancer: current status and future directions. *Breast Cancer Res Treat.* 2024;204(2):193-222. doi:10.1007/s10549-023-07161-1

Fearn N, Llanos C, Dylke E, Stuart K, Kilbreath S. Quantification of breast lymphoedema following conservative breast cancer treatment: a systematic review. *J Cancer Surviv.* 2023;17(6):1669-1687. doi:10.1007/s11764-022-01278-w

Gupta SS, Mayrovitz HN. The Breast Edema Enigma: Features, Diagnosis, Treatment, and Recommendations. *Cureus.* 2022;14(4):e23797. Published 2022 Apr 3. doi:10.7759/cureus.23797

Riches K, Cheung KL, Keeley V. Improving the Assessment and Diagnosis of Breast Lymphedema after Treatment for Breast Cancer. *Cancers (Basel).* 2023;15(6):1758. Published 2023 Mar 14. doi:10.3390/cancers15061758

Shah, C., Zambelli-Weiner, A., Delgado, N. et al. The impact of monitoring techniques on progression to chronic breast cancer-related lymphedema: a meta-analysis comparing bioimpedance spectroscopy versus circumferential measurements. *Breast Cancer Res Treat* 185, 709–740 (2021)

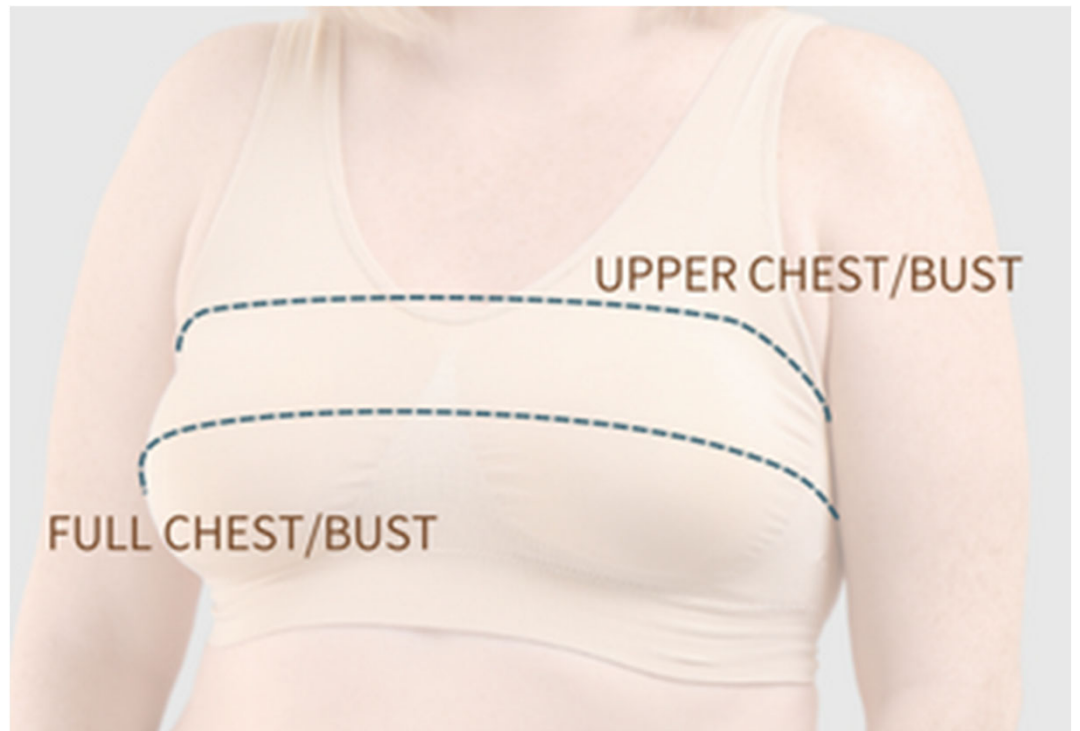
Truncal measurements

Obtain 2 measurements of the trunk at evaluation and 30 days later

Measure patient unclothed

Upper chest

Nipple line



Palpation is essential to assessing fibrosis

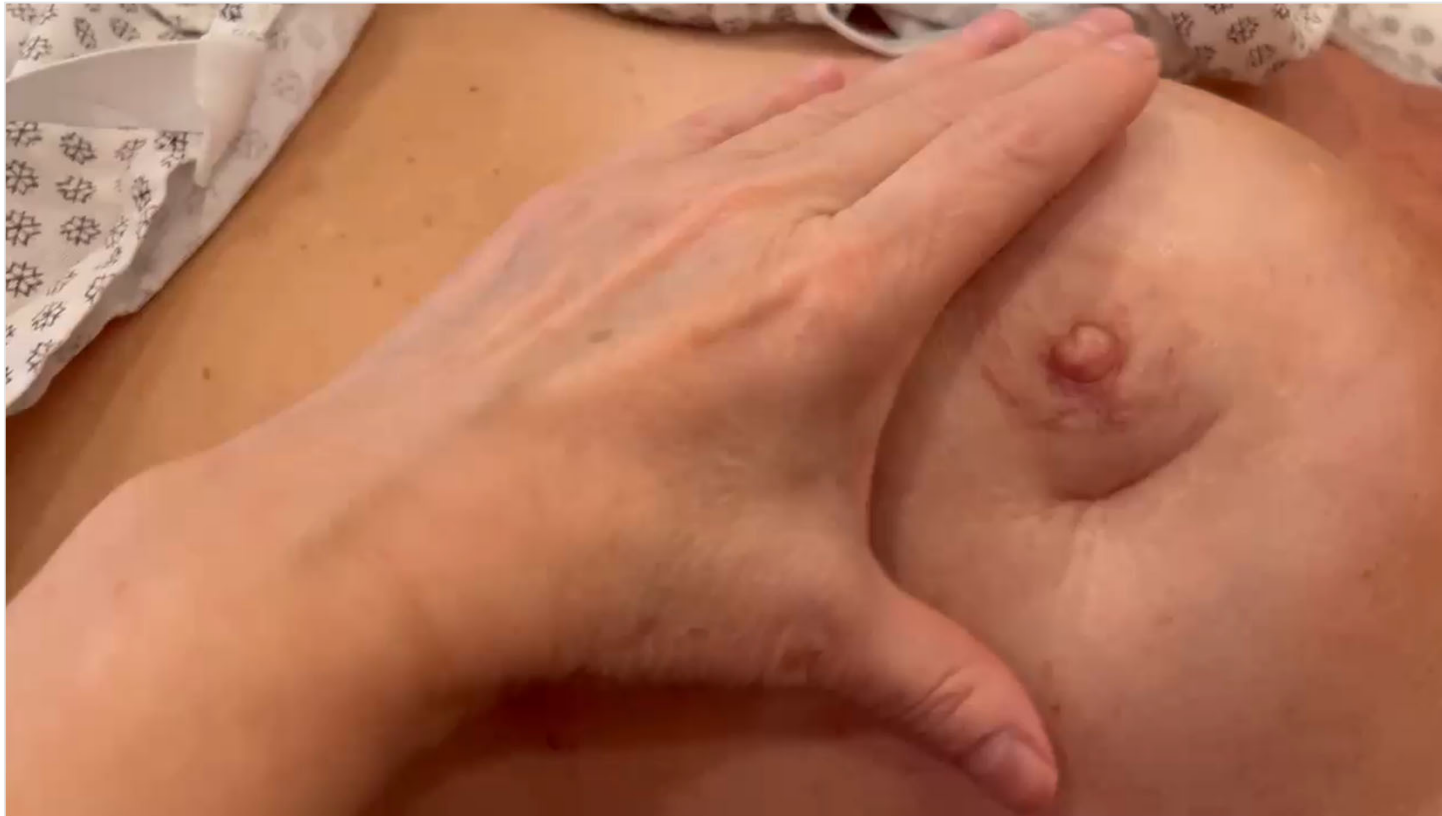
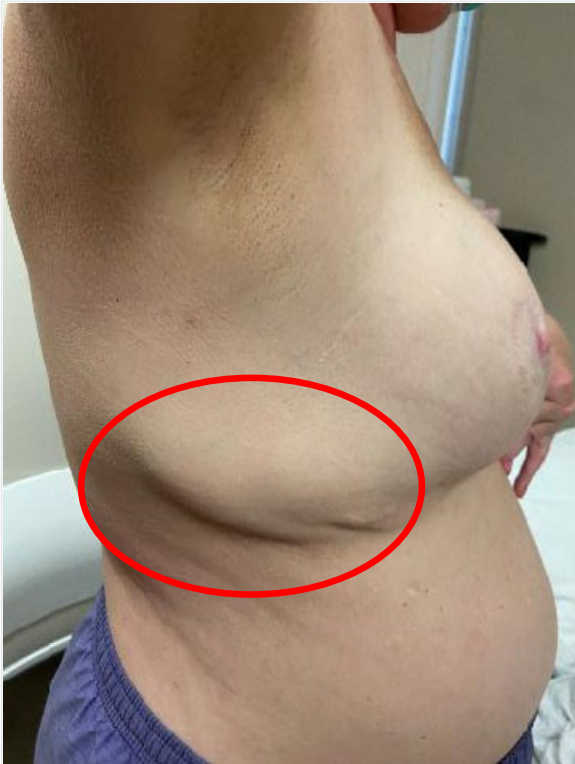
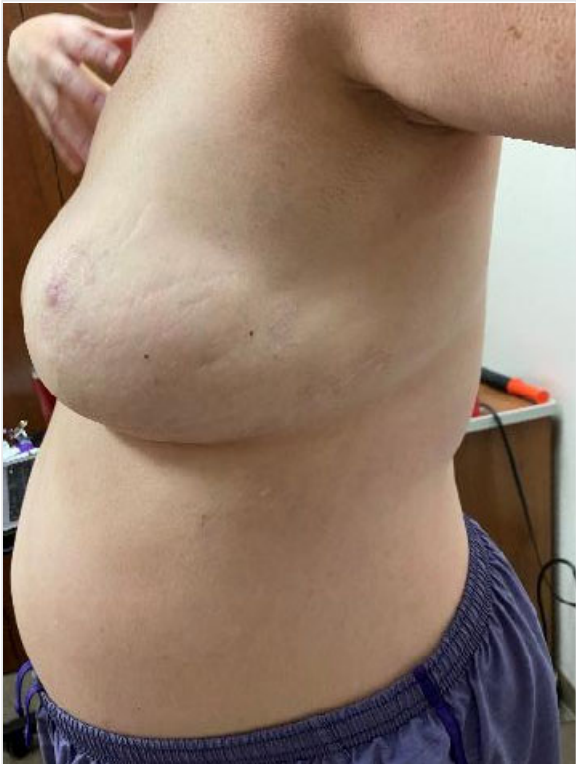Image courtesy by patient consent.

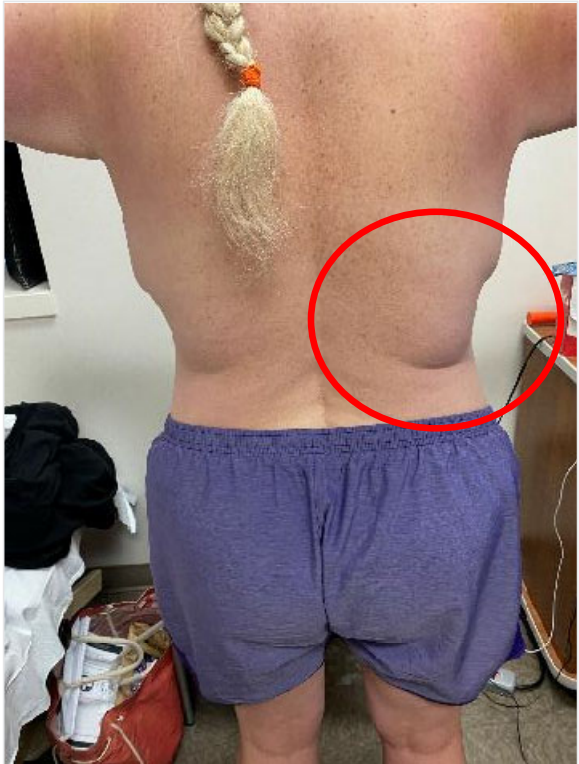Photos for side-by-side comparison



Right trunk



Left trunk



Posterior trunk

Images by patient consent

Range of motion assessment

- Is range of motion affected by fibrosis?
- Is movement painful?
- Do you observe visible evidence of fibrosis before or during the movement?
- Is the patient demonstrating avoidance behaviors?

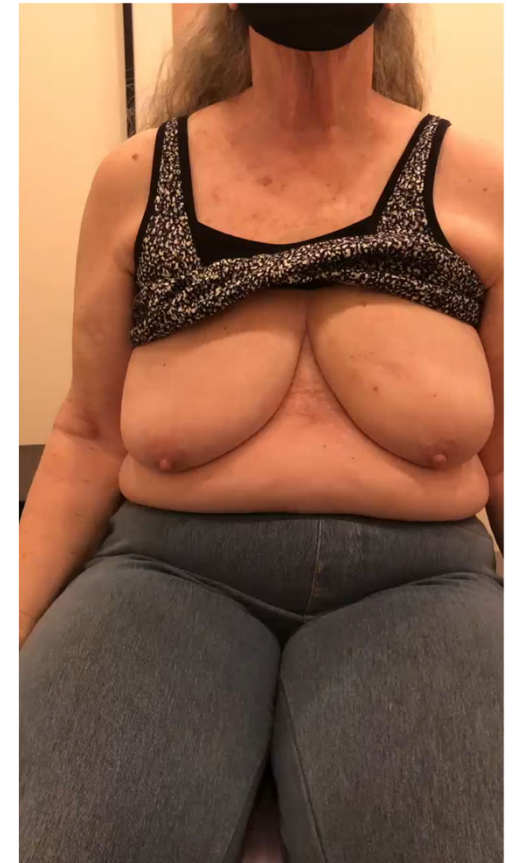


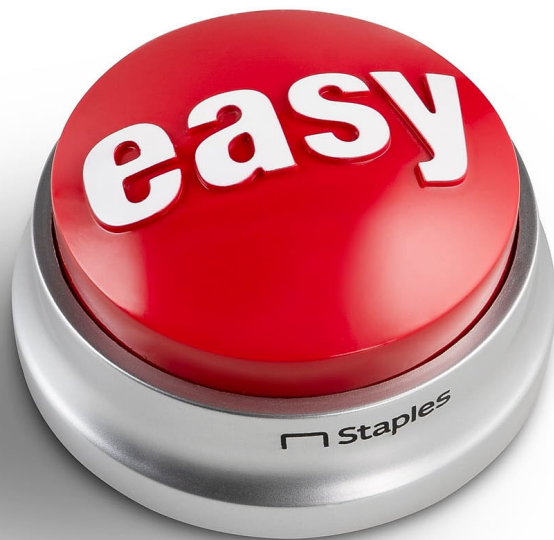Image by patient consent.

Slide 42

MC1 I added the ROM video
Mary Calys, 2026-03-12T15:48:33.430

@LymphPump EMR text replacement

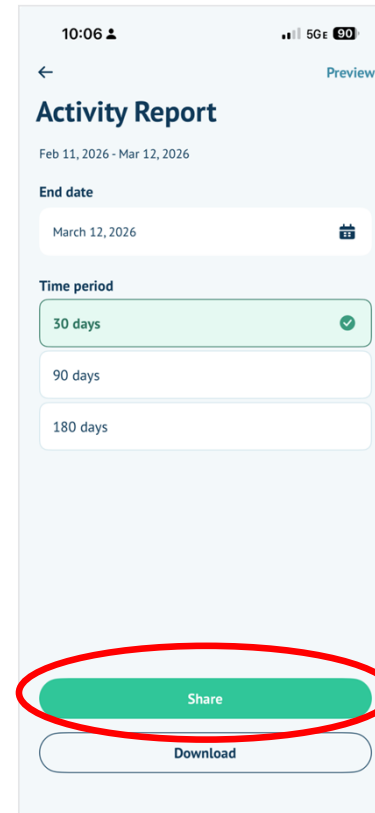
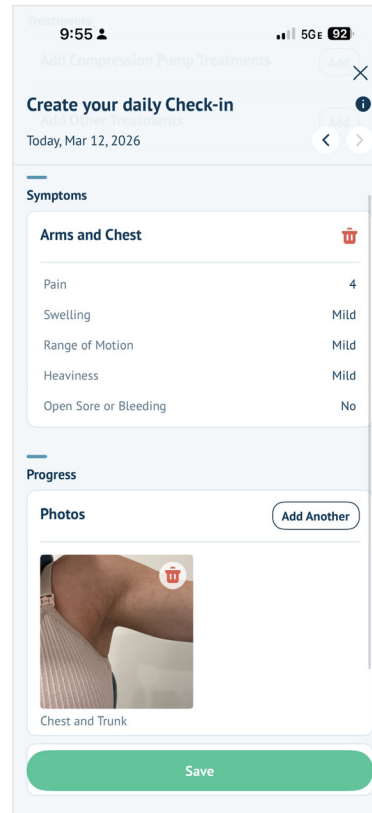
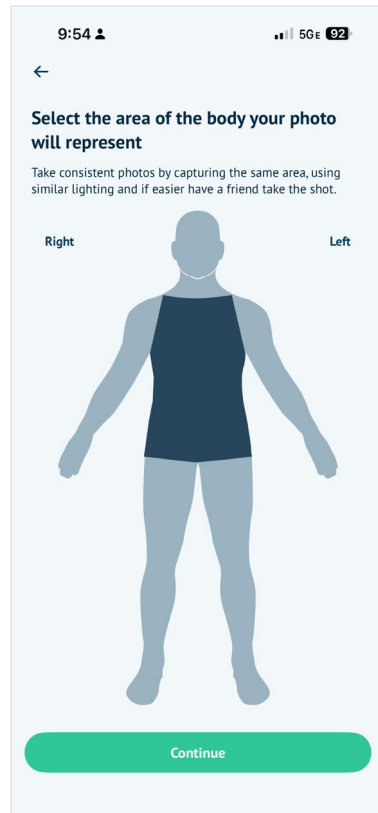
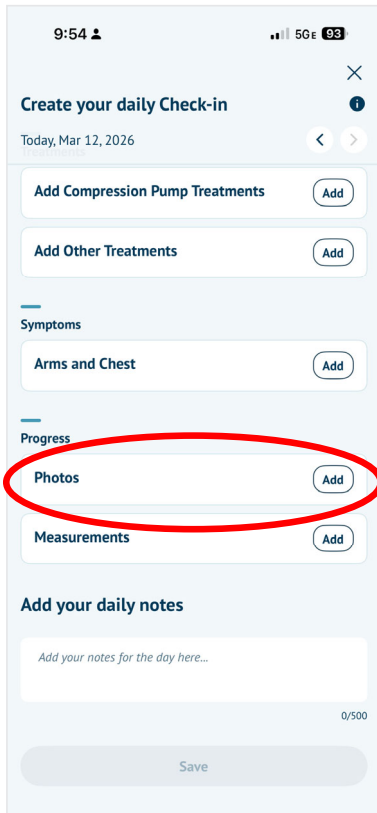
Work smarter, not harder!



@LymphPump includes necessary criteria

- **Lymphedema** symptoms including all affected areas (chest/ trunk)
- Unique **symptoms of severity** (i.e. fibrosis, scarring, hyperpigmentation)
- **Compression, elevation, and exercise** trial (4 weeks required by insurance)
- **Why** patient is recommended for the Flexitouch or Nimbl
- **Measurements** of affected areas (i.e. arm, chest, trunk)

Obtain photos in Kylee



Symptom screeners

Breast Cancer-Related Lymphedema Patient Symptom Screener

CHECK ALL THAT APPLY

Arm symptoms	Trunk symptoms
<input type="checkbox"/> Arm swelling	<i>Note: Differences in bra fit, including indentation at bands/straps or changes in band and cup size, are common indicators of truncal swelling.</i>
<input checked="" type="checkbox"/> Arm heaviness	
<input type="checkbox"/> Arm firmness	
<input type="checkbox"/> Increased arm temperature	
<input type="checkbox"/> Seroma formation (fluid buildup under the surface of the skin)	
<input checked="" type="checkbox"/> Arm tightness	
<input type="checkbox"/> Limited arm movement	
<input type="checkbox"/> Tingling in affected arm	
<input checked="" type="checkbox"/> Arm aching	
<input type="checkbox"/> Limited fingers movement	
<input type="checkbox"/> Limited elbow movement	
<input type="checkbox"/> Limited wrist movement	
<input type="checkbox"/> Limited shoulder movement	
<input type="checkbox"/> Stiffness in the affected arm	
<input type="checkbox"/> Burning in the affected arm	
<input type="checkbox"/> Arm redness	
<input type="checkbox"/> Numbness in the affected arm	
<input type="checkbox"/> Tenderness in the affected arm	
<input type="checkbox"/> Pain in the affected arm	
Total number of reported arm symptoms:	Breast, chest and collarbone area:
	<input type="checkbox"/> Swelling or puffiness
	<input type="checkbox"/> Heaviness or fullness
	<input type="checkbox"/> Tightness or firmness
	<input type="checkbox"/> Dimpled hair follicles on breast; orange peel appearance
	Side and axilla (armpit):
	<input checked="" type="checkbox"/> Swelling or puffiness
	<input type="checkbox"/> Heaviness or fullness
	<input type="checkbox"/> Tightness or firmness
	<input type="checkbox"/> Feeling of a "ball" preventing arm from resting at side
	<input type="checkbox"/> Feeling of a cord pulling with motion
	Shoulder and back:
	<input type="checkbox"/> Swelling or puffiness
	<input type="checkbox"/> Heaviness or fullness
	<input type="checkbox"/> Tightness or firmness
	<input type="checkbox"/> Limited range of motion
	<input type="checkbox"/> Pain

Common symptoms associated with lymphedema and fibrosis

- Firmness
- Tightness
- Limited range of motion
- Stiffness
- Redness
- Numbness
- Tenderness
- Pain


Patient-reported symptoms are instrumental in diagnosing early-stage lymphedema,¹ especially when pre-treatment measurements are not available²

1. Fu MR, Axelrod D, Cleland CM, et al. Symptom report in detecting breast cancer-related lymphedema. *Breast Cancer* (Dove Med Press). 2015;7:345–352.

2. Sun, F., Skolny, M.N., Swaroop, M.N. et al. The need for preoperative baseline arm measurement to accurately quantify breast cancer-related lymphedema. *Breast Cancer Res Treat* 157, 229–240 (2016).

Symptom screener use case example

1. Introduce screener @ prehab evaluation
2. Patient instructed to review symptoms monthly
3. Kylee App notifications set for monthly check
4. Patient instructed to notify therapist of changes




SYMPTOM SCREENER

Breast cancer-related lymphedema patient symptom screener.

CHECK ALL THAT APPLY

Arm symptoms	Trunk symptoms
<input type="checkbox"/> Arm swelling	<i>Note: Differences in bra fit, including indentation at bands/straps or changes in band and cup size, are common indicators of breast swelling.</i>
<input type="checkbox"/> Arm heaviness	Breast, chest and collarbone area:
<input type="checkbox"/> Arm firmness	<input type="checkbox"/> Swelling or puffiness
<input type="checkbox"/> Increased arm temperature	<input type="checkbox"/> Heaviness or fullness
<input type="checkbox"/> Seroma formation (fluid buildup under the surface of the skin)	<input type="checkbox"/> Tightness or firmness
<input type="checkbox"/> Arm tightness	<input type="checkbox"/> Dimpled hair follicles on breast or orange peel appearance
<input type="checkbox"/> Limited arm movement	Side and axilla (armpit):
<input type="checkbox"/> Tingling in affected arm	<input type="checkbox"/> Swelling or puffiness
<input type="checkbox"/> Arm aching	<input type="checkbox"/> Heaviness or fullness
<input type="checkbox"/> Limited fingers movement	<input type="checkbox"/> Tightness or firmness
<input type="checkbox"/> Limited elbow movement	<input type="checkbox"/> Feeling of a "ball" preventing arm from resting at side
<input type="checkbox"/> Limited wrist movement	<input type="checkbox"/> Feeling of a cord pulling with motion
<input type="checkbox"/> Limited shoulder movement	Shoulder and back:
<input type="checkbox"/> Stiffness in the affected arm	<input type="checkbox"/> Swelling or puffiness
<input type="checkbox"/> Burning in the affected arm	<input type="checkbox"/> Heaviness or fullness
<input type="checkbox"/> Arm redness	<input type="checkbox"/> Tightness or firmness
<input type="checkbox"/> Numbness in the affected arm	<input type="checkbox"/> Limited range of motion
<input type="checkbox"/> Tenderness in the affected arm	<input type="checkbox"/> Pain
<input type="checkbox"/> Pain in the affected arm	

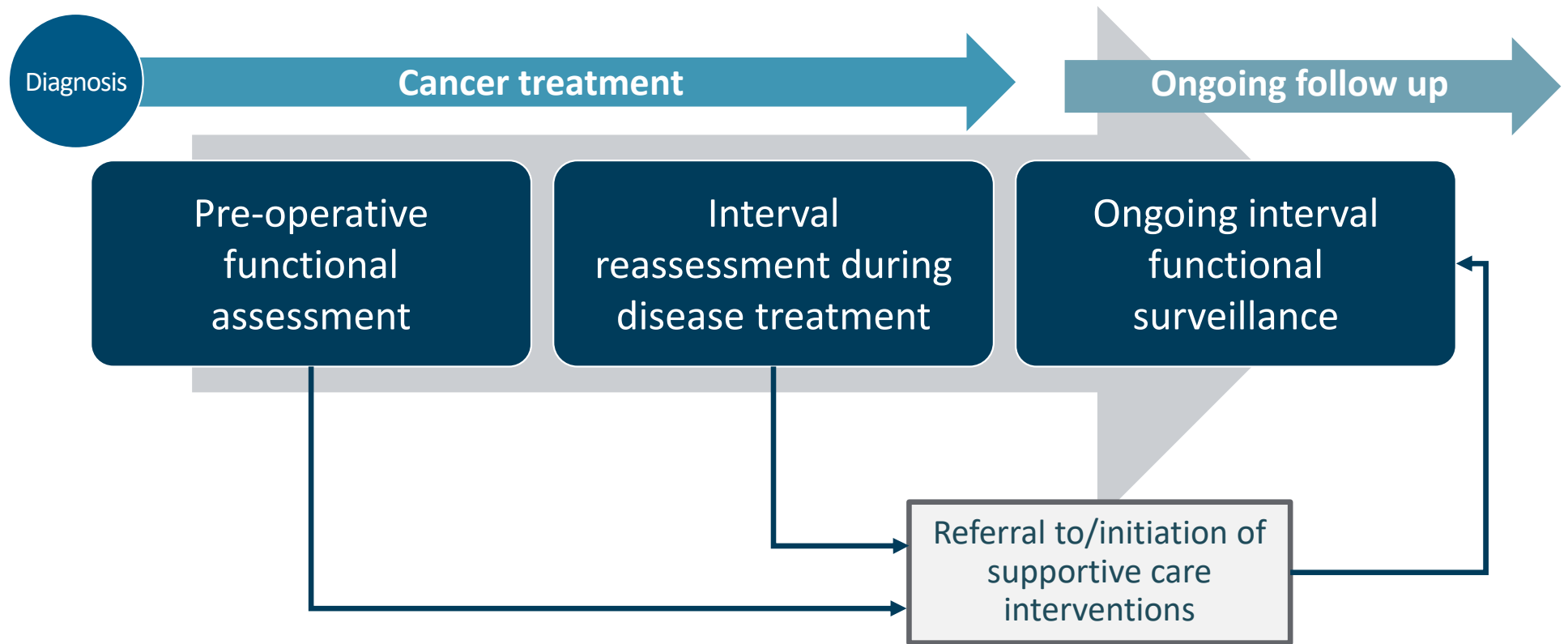
Kylee® is an easy-to-use, free mobile app to help you understand chronic swelling, track and manage your symptoms and live your best life! Download Kylee today!



TACTILE MEDICAL

Prospective surveillance

Prospective surveillance model



Lymphedema patient experience within healthcare system

Baseline characteristics and pre-oncologic care

Cross-sectional study

1,941 patients

- 51.4% with cancer history
 - 65.3% received lymphadenectomy and radiation initially
- 23-item questionnaire or global patient registry self-report

66.2%

Reported **not** discussing lymphedema with their healthcare provider

86.4%

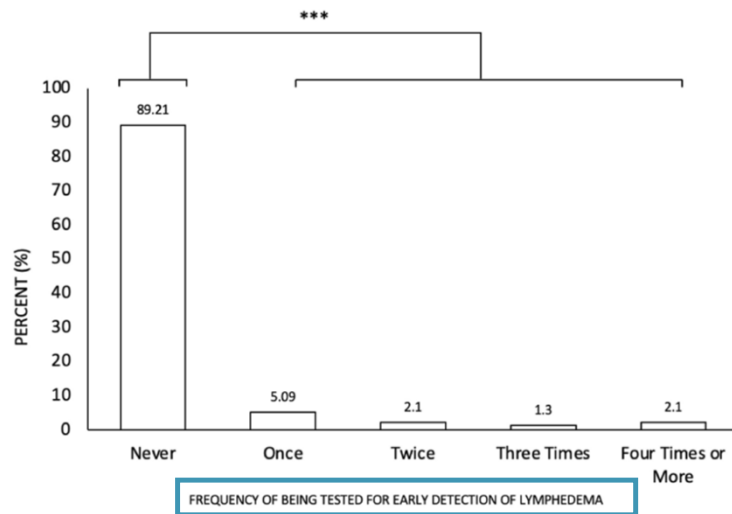
Reported **not** receiving educational materials on lymphedema

90.6%

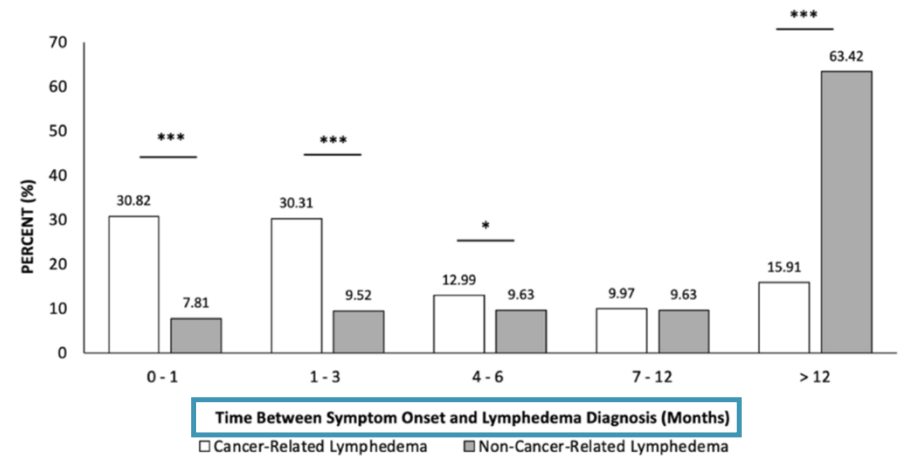
Reported **not** receiving prescription for prophylactic compression garments

Lymphedema patient experience within healthcare system

During cancer treatment



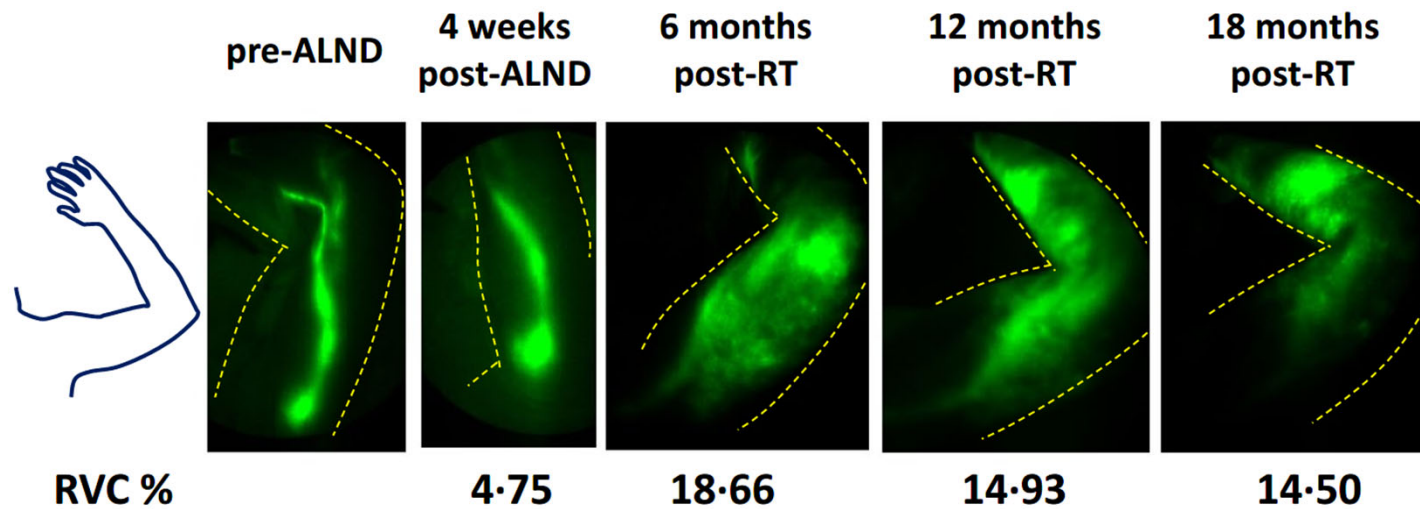
After cancer treatment



89% were never tested for early detection of lymphedema
 77% were never questioned about lymphedema
 79% were never examined for lymphedema

58% developed lymphedema symptoms within 12 months
 61% were diagnosed with lymphedema within 3 months of symptoms

Lymphatic dysfunction is evident long before visible swelling



Lymphatic dysfunction appeared on imaging an average of 8 months before arm swelling

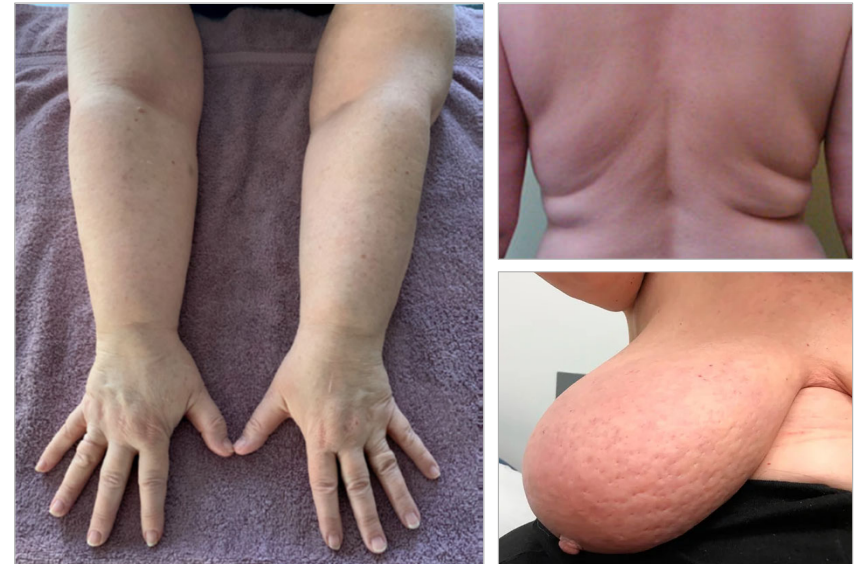Aldrich MB, Rasmussen JC, DeSnyder SM, Woodward WA, Chan W, Sevick-Muraca EM, Mittendorf EA, Smith BD, Stauder MC, Strom EA, Perkins GH, Hoffman KE, Mitchell MP, Barcenas CH, Isales LE, Shaitelman SF. Prediction of breast cancer-related lymphedema by dermal backflow detected with near-infrared fluorescence lymphatic imaging. Breast Cancer Res Treat. 2022 Aug;195(1):33-41.

Patients at high risk for BCRL

Risk stratification can help to inform surveillance practices

Patient characteristics

- Four or more positive lymph nodes, with ≥ 10 higher risk
- Received radiation therapy
- Exhibits even mild swelling one month after surgery
- BMI over 30 prior to cancer treatment
- Taxane-based chemotherapy



(A)

Bundred N, Foden P, Todd C, et al. Increases in arm volume predict lymphoedema and quality of life deficits after axillary surgery: A prospective cohort. *Br J Cancer*. 2020;123(1):17-25.
Nguyen TT, Hoskin TL, Habermann EB, Chevillat AL, Boughey JC. Breast Cancer-Related Lymphedema Risk is Related to Multidisciplinary Treatment and Not Surgery Alone: Results from a Large Cohort Study. *Ann Surg Oncol*. 2017 Oct;24(10):2972-2980.
Rockson SG. Lymphedema after breast cancer treatment. *N Engl J Med*. 2018;379(20):1937-1944.

Treatment options

Slide 53

MG1 Feedback in this section would be to consider: what problem would we solve for the treating therapist? That ties into the treatment option

Melissa Geraci, 2026-02-25T16:34:30.059

Pair skilled therapy with patient-centered home program for optimal results

In-clinic skilled therapy (1-10 visits)



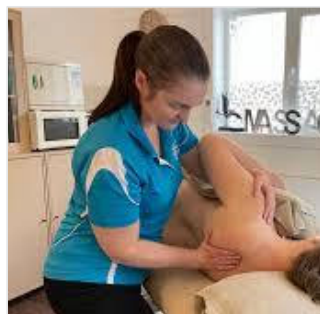Education on symptoms



Stretches and exercises




Static compression




Scar tissue massage

At-home program (lifelong)



Stretches and exercises



Static compression



Manual lymphatic drainage massage

Slide 54

HL1 [@Mary Calys] I combined 2 slides as you recommended - let me know what you think!
Helen Laktas, 2025-10-06T17:23:30.037

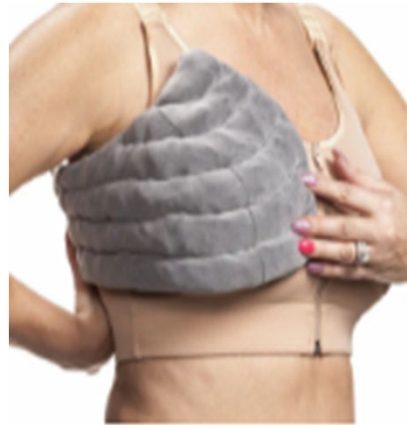MC1 0 I think it looks good. I changed slide 31, take a look.
Mary Calys, 2025-10-06T17:36:18.289

Static compression options



Comfiwave Breast Band

Textured liner/night compression



Solaris

Channel foam pads



WearEase

Textured compression bras



Circaid Reduction Kit Vest

Velcro reduction kit

Photo credit:Verbelen H, Tjalma W, Dombrecht D, Gebruers N. Breast edema, from diagnosis to treatment: state of the art. *Arch Physiother.* 2021;11(1):8. Published 2021 Mar 29. doi:10.1186/s40945-021-00103-4
<https://lymphoedemaeducation.com.au/compression-for-breast-oedema/haddenham-healthcare-compression-for-breast-oedema/breast-band-comfiwave-1/>
<https://www.amoena.com/us-en/breast-forms/partial-breast-shapers/>
https://www.wearase.com/products/breast-swell-spot-sp-09?srsltid=AfmBOorrXGI_jpmyRwBxXqFLTzQTmhkWAZs_-aieZwzGJev6DGuoFQC_
https://www.wearase.com/products/karena-textured-compressionbra?srsltid=AfmBOooMznVTGvT0tjppjF5r60PaTYBQrp2GoE2dUyPCCxclR7N_-zs

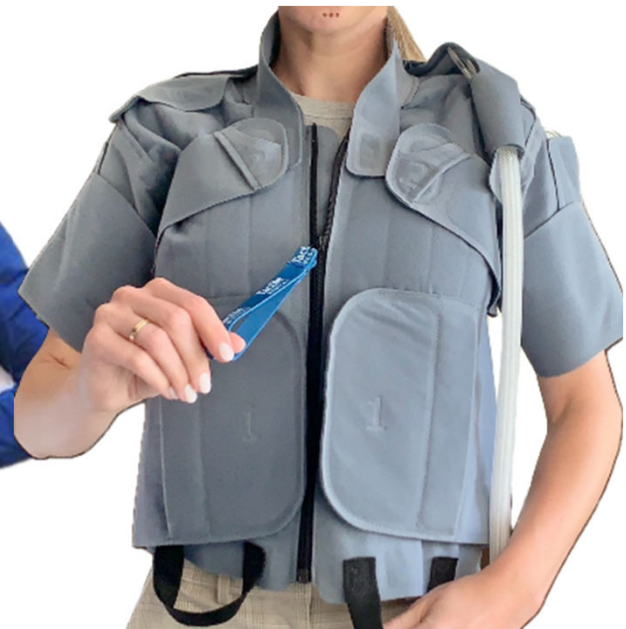Evolution of flexitouch for breast cancer survivorship



2003
Flexitouch classic



2017
Flexitouch plus



2023
Flexitouch plus confortease

Slide 56

- MG1** Would love to hear more on goal of this slide
Melissa Geraci, 2026-02-25T16:33:15.399
- MG1 0** Do we take 2023 and break it out with this image + one image that includes option with arm attached so to not cnonfuse that its not an option to treat arm?
Melissa Geraci, 2026-02-25T16:33:39.873
- MC1 1** I believe the original goals was to show that the garments are updated in response to current research (ICG findings) and clinician/patient feedback. I do like your idea to break out the 2023 image.
Mary Calys, 2026-03-12T15:50:38.391

Flexitouch Plus ComfortEase vest is designed for breast and truncal lymphedema

Alternative lymph drainage regions for breast clearance

90% demonstrated collateral drainage pathways

- Parasternal
- Contralateral axilla
- Intercostal
- Clavicular

0% drained to the inguinals

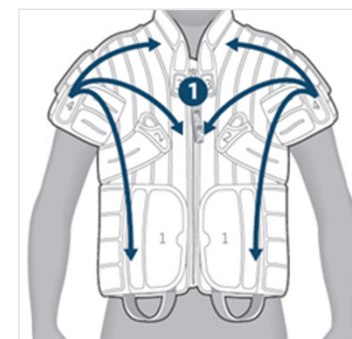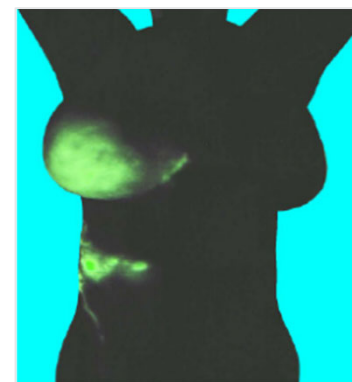
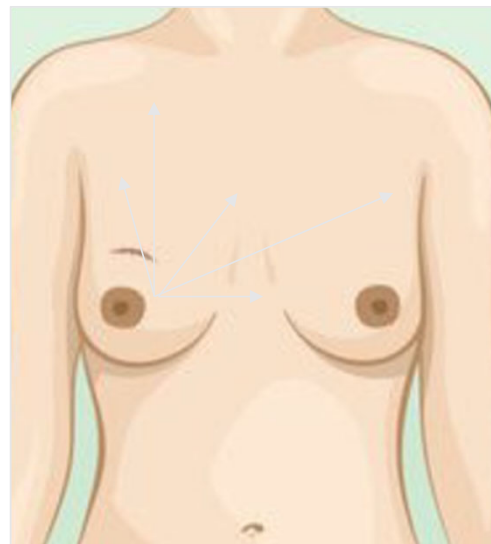

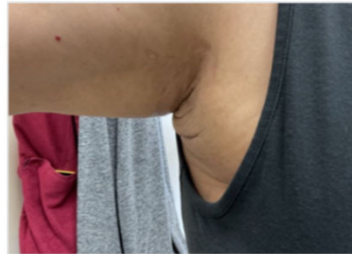
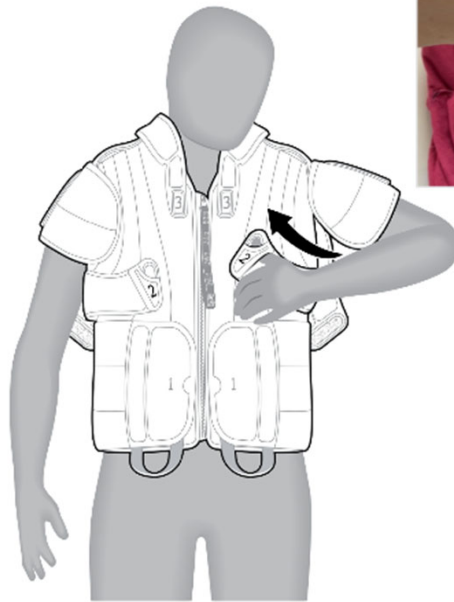Photo cred: <https://kalickcancer.com/surgery/mastectomy-v-lumpectomy/>
Heydon-White A, Suami H, Boyages J, Koelmeyer L, Peebles KC. Assessing breast lymphoedema following breast cancer treatment using indocyanine green lymphography. *Breast Cancer Res Treat.* 2020;181(3):635-644. doi:10.1007/s10549-020-05661-y

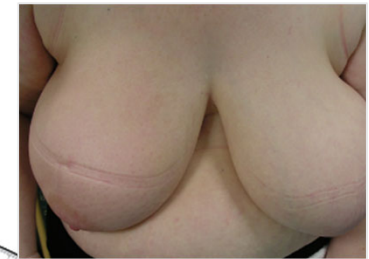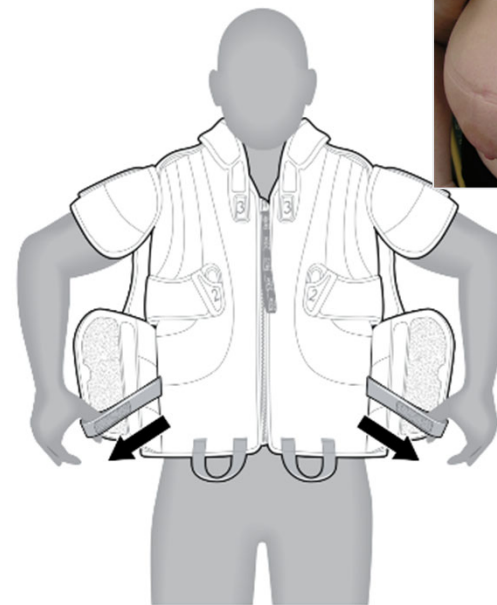Patient feedback influenced flexitouch vest design

Axillary tightness



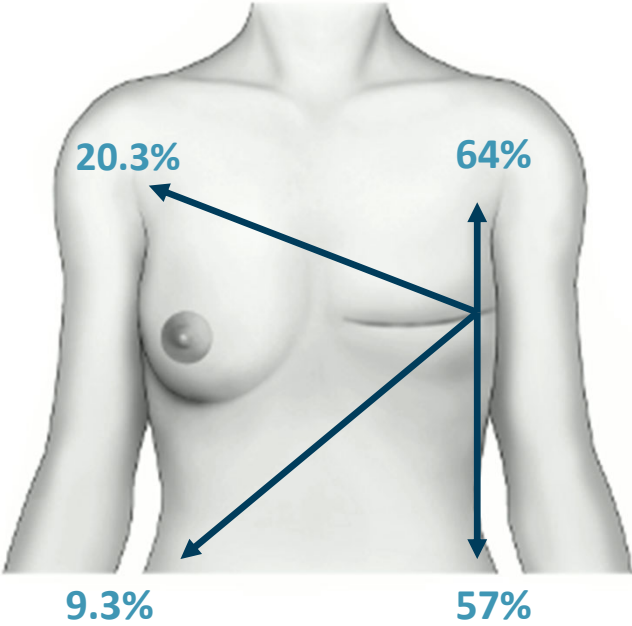
Adjustable **Axillary Straps** contour patient's shape to provide comprehensive treatment

Breast edema

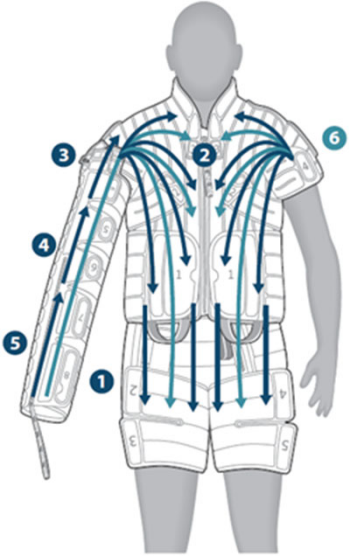


Adjustable **Cinch Straps (black)** and **Waist Mits (Gray)** contour tissue to accommodate variety of shapes

Alternative lymph drainage regions from the chest wall/trunk

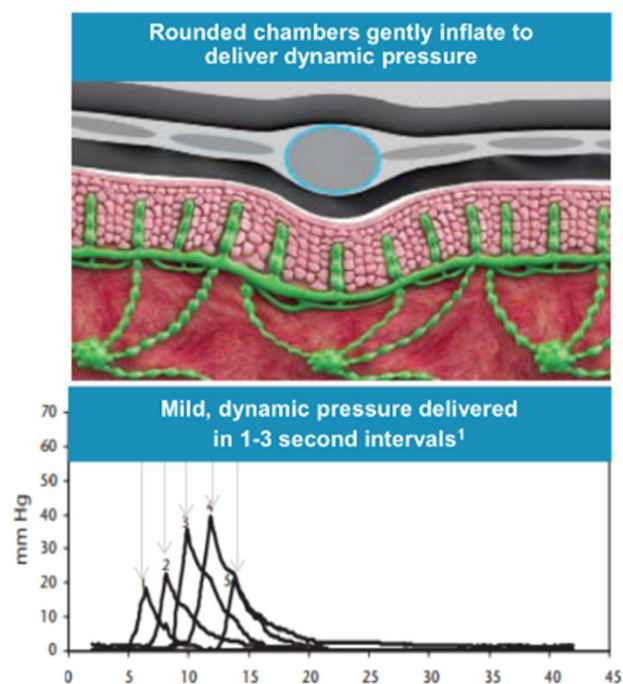


© Sam and Amy Collins

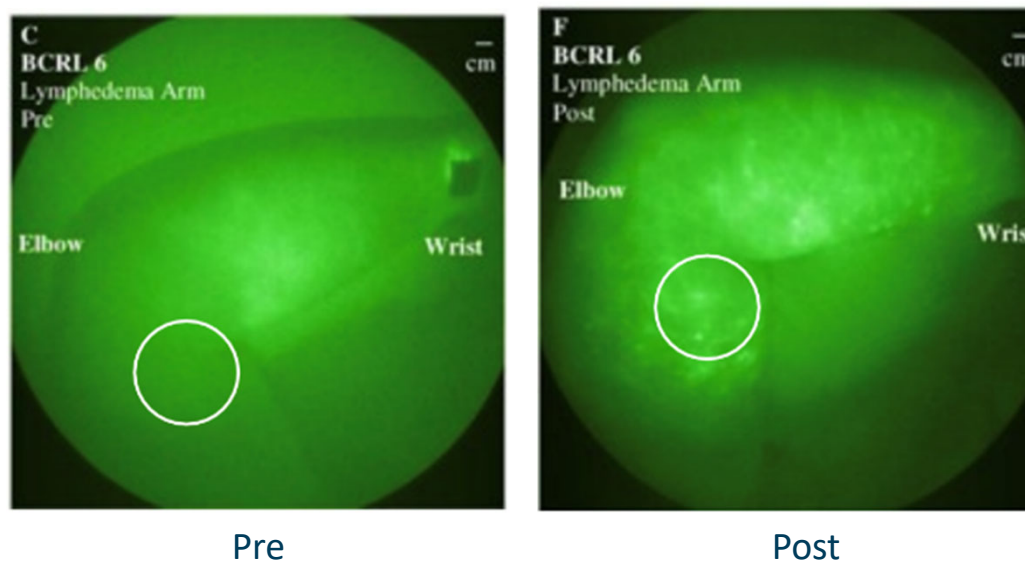


Mehta M, Moroni E, Fishman J, De La Cruz C. D25. Alternative Patterns of Superficial Lymphatic Drainage in the Breast and Trunk after Breast Cancer Surgery. *Plast Reconstr Surg Glob Open*. 2023 Apr 26;11(4 Suppl):74. doi: 10.1097/01.GOX.0000934712.36562.77.

Flexitouch is proven to stimulate lymphatic function through unique mechanism of action



Near-infrared fluorescence lymphangiography shows lymph protein movement toward axilla²



1. Mayorvitz, H.N. et al. (2007) Interface Pressures Produced by Two Different Types of Lymphedema Treatment Devices. *Physical Therapy*. 007;Vol.87(10)1379-1388.

2. Adams, K.E. et al. (2010) Direct Evidence of Lymphatic Function Improvement After Advanced Pneumatic Compression Device Treatment of Lymphedema. *Biomed Opt. Express*. 2010 Jul 15; 1(1): 114-125.

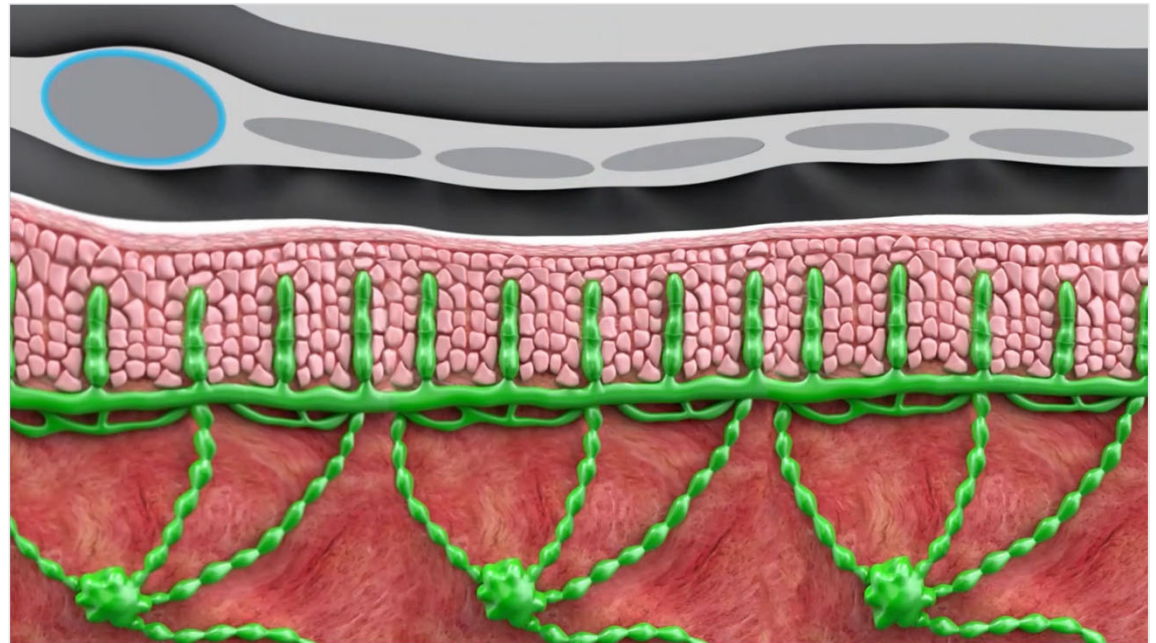
Flexitouch Plus: Automated self-MLD

Unique chamber design supports gentle dynamic mechanism of action that simulates MLD

Provides truncal/proximal clearance

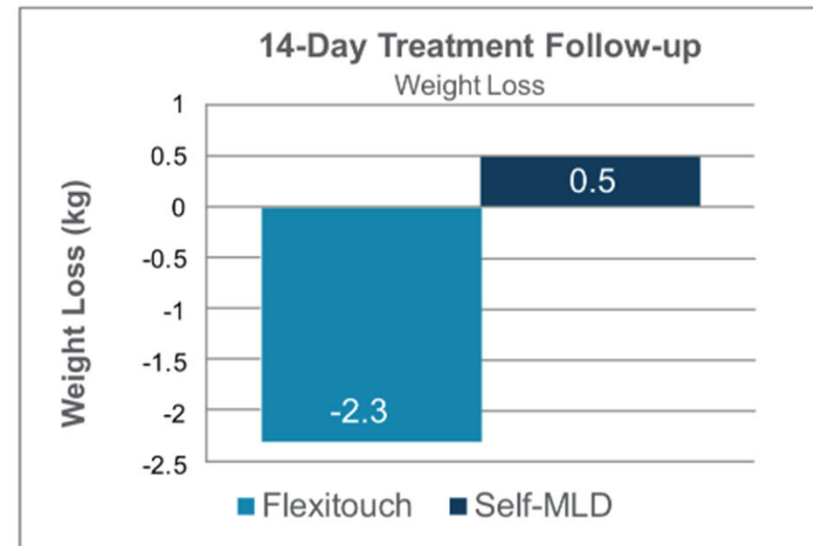
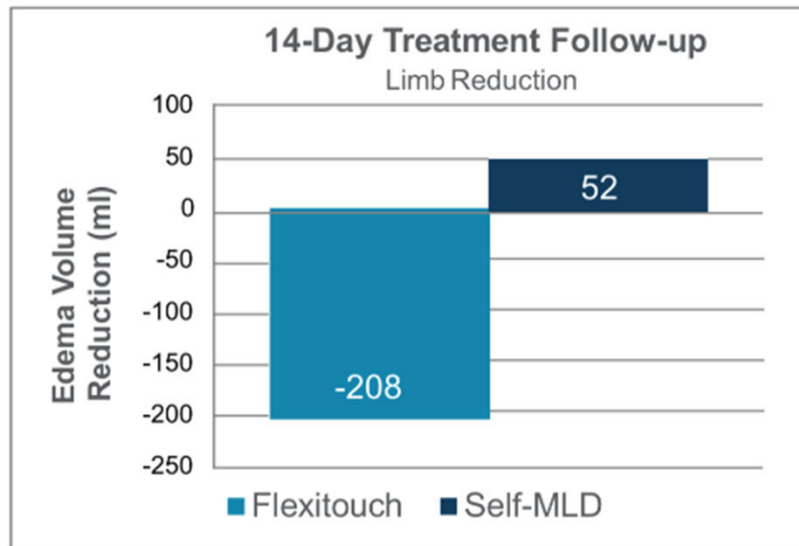
Customized treatment

- Multiple programs available
- Multiple pressure setting options



Flexitouch is more effective than MLD for self-management: randomized crossover trial

Patients can self-manage better when provided with Flexitouch as a tool

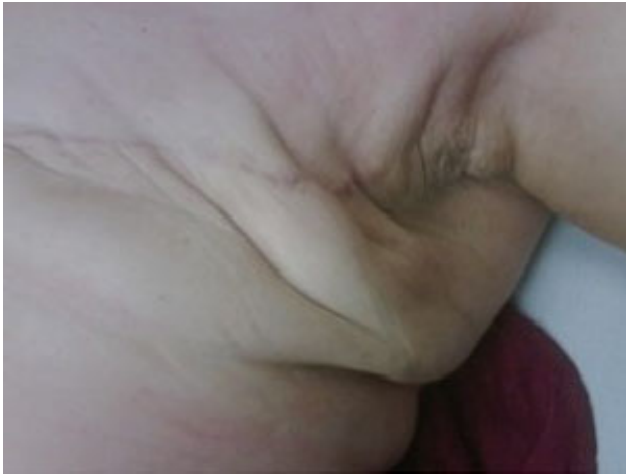

These results were achieved even after receiving professional therapy

BK1 Update the notes

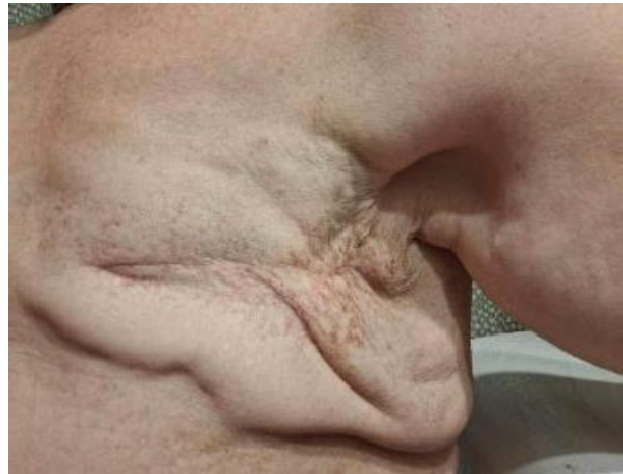Brittani Knific, 2023-02-21T17:12:13.217

Breast cancer patient case study over 13 years



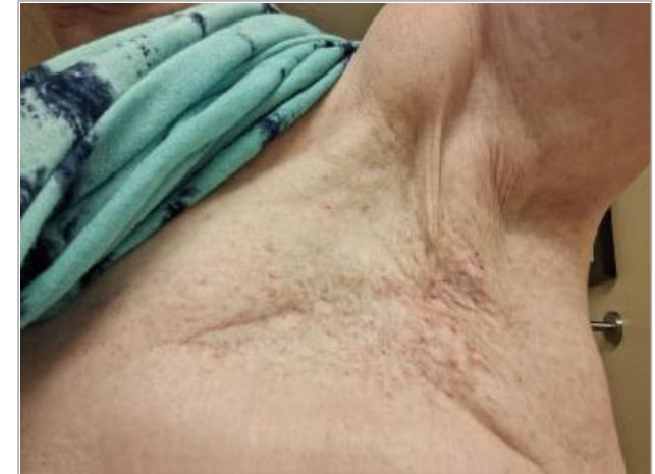2011

Post-mastectomy
Post-chemotherapy
Pre-radiation



May 2024

13 years post-radiation
Initiated PCD use



July 2024

2 Months of PCD use

SE1

Such great photos!

Susan Ellenson, 2024-02-01T20:58:57.106

Frequently asked questions

Slide 64

MG1 Feedback here- is there ways to highlight what we do vs. competition without explicitly naming and keep it positive?

For example pressure- we target this pressure and here is why we don't want pressure "at hoc!" for pts

Melissa Geraci, 2026-02-25T16:36:13.576

MG1 0 Think of the top 2 competitors for revival- what is the messaging they sell on?

Melissa Geraci, 2026-02-25T16:36:33.726

Special considerations with MLD/Flexitouch

Precautions

- Jackson Pratt (JP) drain
- Acute radiation dermatitis
- Chemotherapy with IV/ports
- Breast expanders
- Flap surgeries
- Infections: wait 48–72 hours

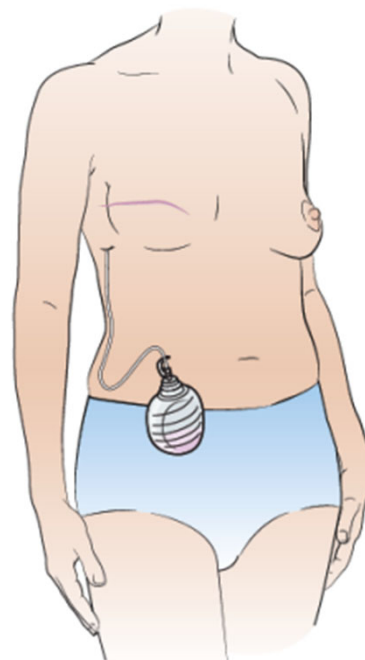


Photo credit: Jackson Pratt Drain. Memorial Sloan Kettering Cancer Center

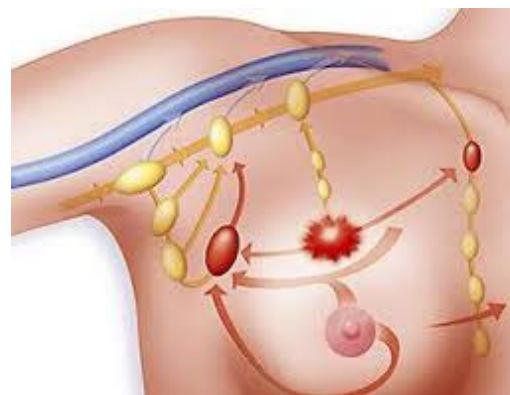


Photo credit: Peoplebeatingcancer.org

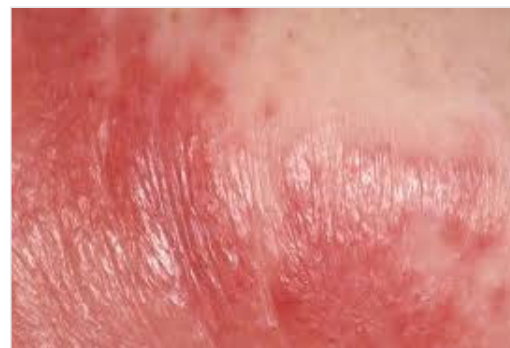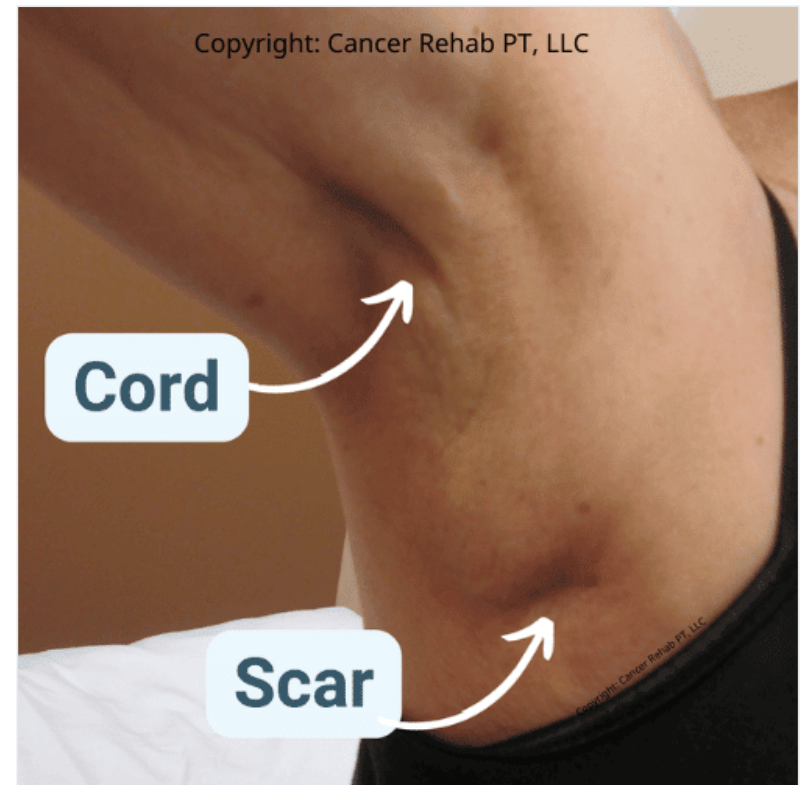
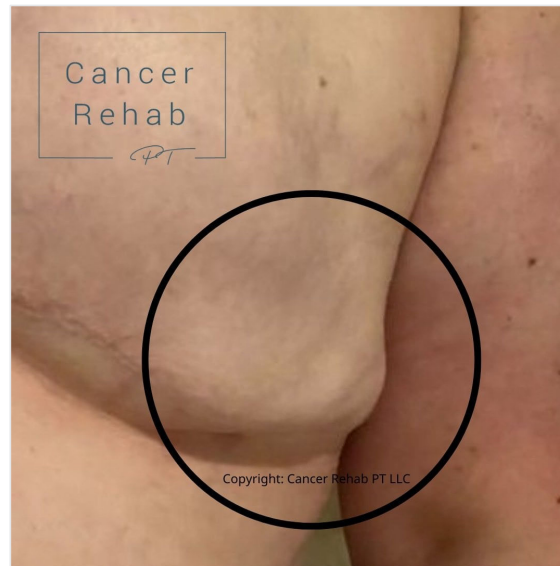


Photo credit: On health.com

Special considerations with MLD/Flexitouch

Treatment okay over:

- Breast implants
- Axillary webbing
- Seromas



Flexitouch treatment FAQs

Q: My patient has pendulous breast tissue; how can she target the inferior breast fibrosis?

A: Consider inserting a chip pack; keep it in place by wearing a camisole underneath the Flexitouch vest.

Q: Do you have any positioning recommendations to enhance treatment?

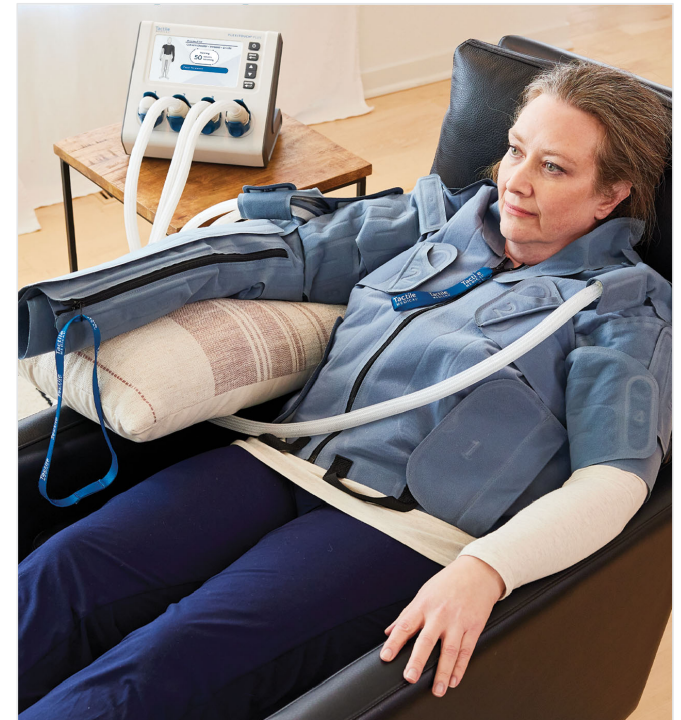A: Patient can be positioned side lying allowing gravity to assist with breast positioning for optimal coverage.

Q: Can the Flexitouch vest be used to treat breast lymphedema without the arm?

A: Yes, the vest can be used with or without the arm attachment depending on where they would like to focus treatment based on symptom presentation.

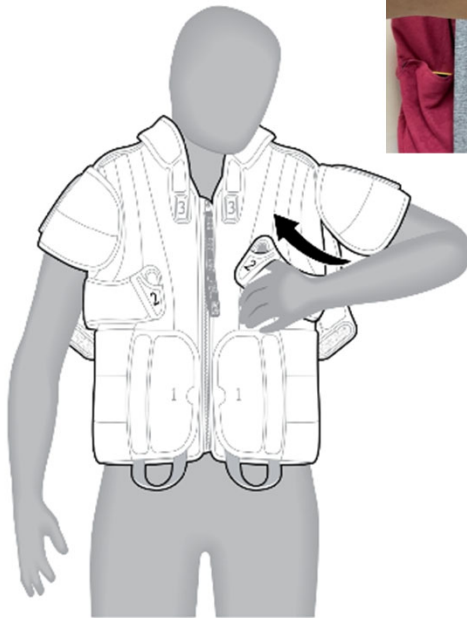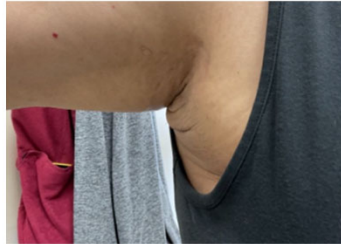Q: Can the treatment times be modified?

A: Yes, as little as 12 minutes for vest-only treatment or 1hour including chest, trunk, and extremity as needed



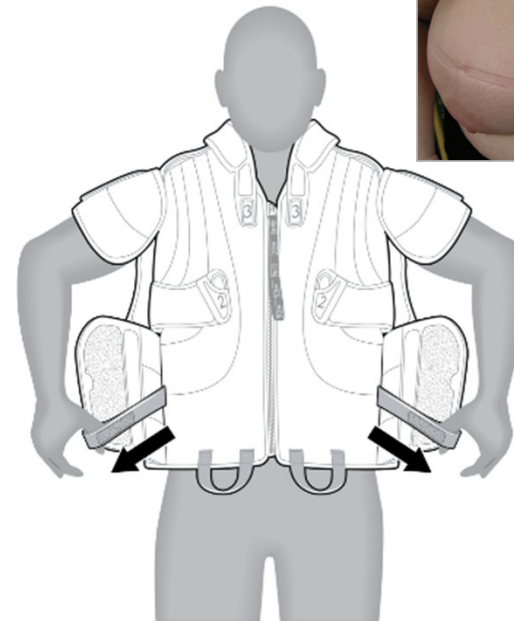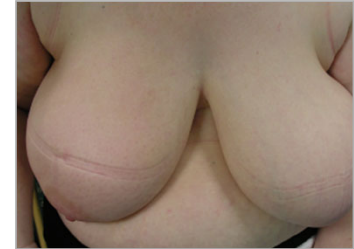Patient feedback influenced Flexitouch vest design

Axillary tightness



Adjustable **Axillary Straps** contour patient's shape to provide comprehensive treatment

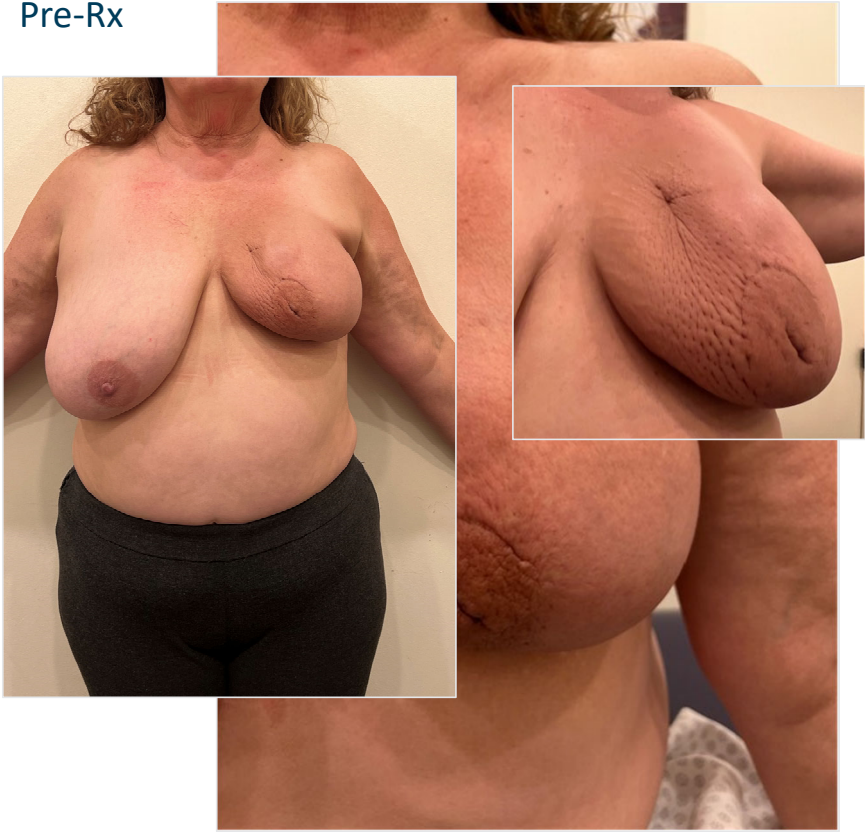Breast edema



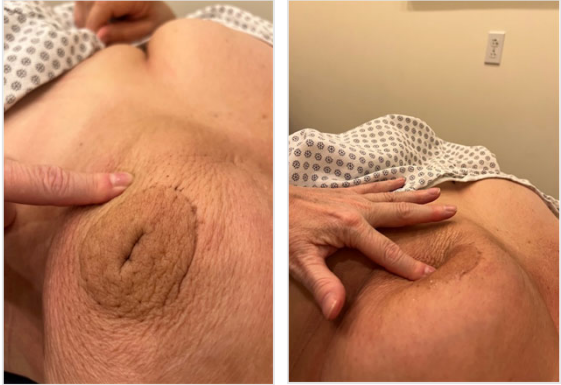Adjustable **Cinch Straps (black)** and **Waist Mits (Gray)** contour tissue to accommodate variety of shapes

Case study: Chest radiation fibrosis

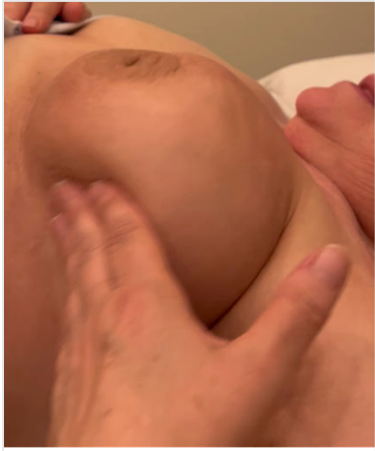Pre-Rx



1st Rx
11-30-23

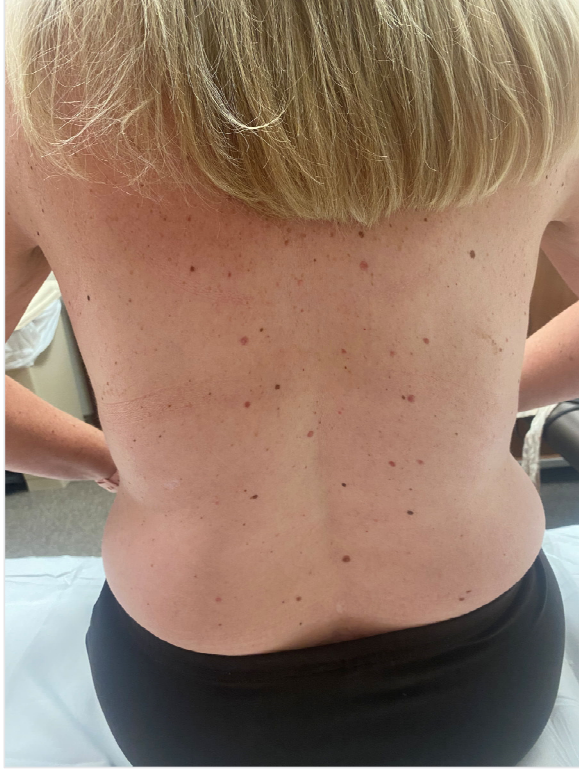
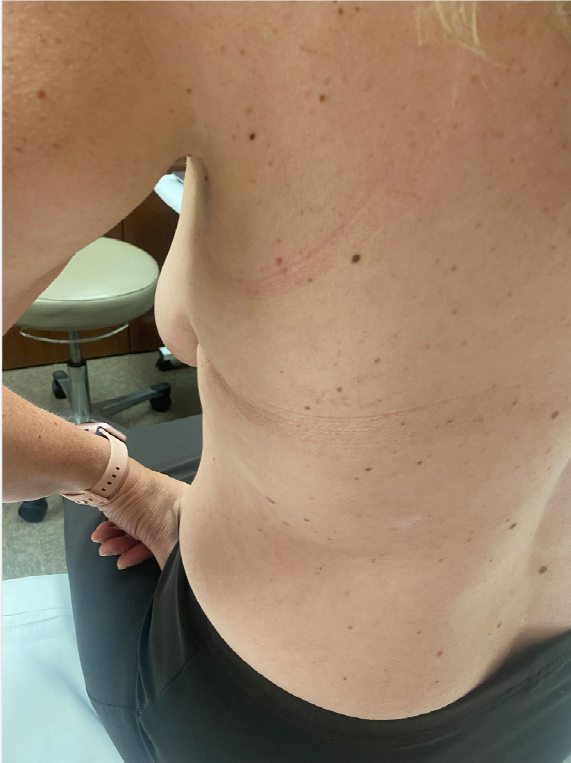
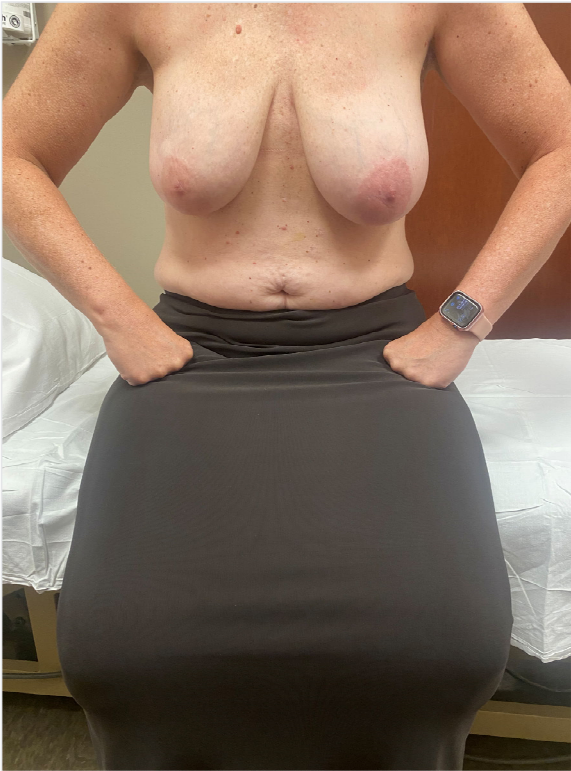2nd Rx
3-5-24



Images provided with patient consent

Case study: Breast Swelling



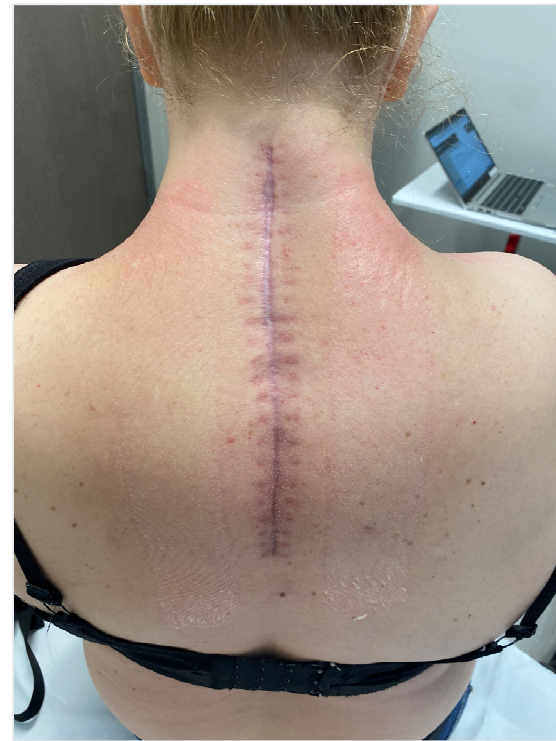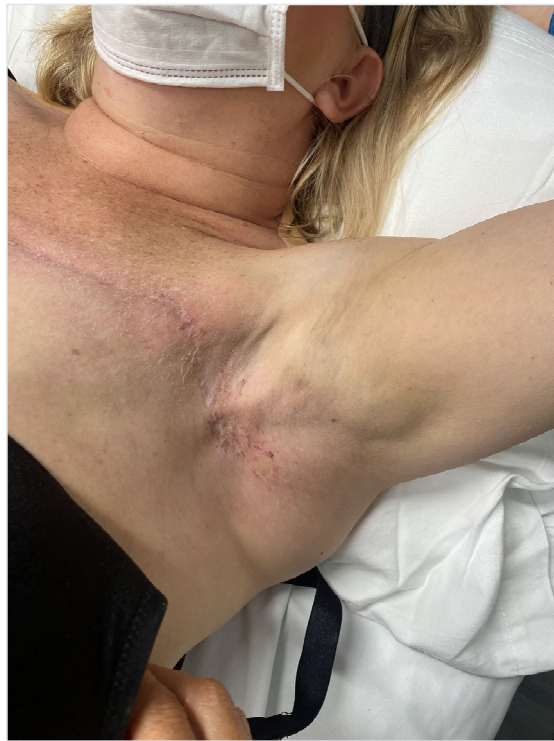Images provided with patient consent

Slide 70

HL1 [@Mary Calys] Can you include a breast lymphedema case study?
Helen Laktas, 2026-03-11T17:17:45.724

MC1 0 Take a look at slides 69, 70 and 71
Mary Calys, 2026-03-12T19:53:15.752

Case study: Skin induration, chest wall adhesion, axillary cording, radiation fibrosis, joint stiffness



Images provided with patient consent

Resources

Tactile Medical resources

These items will be included in your Tactile Medical welcome packet

Breast cancer-related lymphedema has evolved — and so has insurance coverage.

40% of breast cancer survivors experience lymphedema¹, which leads to a lower quality of life.



Assess your patients for the following symptoms* to determine if they qualify for a Flexitouch[®] Plus system to help them manage their condition at home:

- Fibrosis
- Scarring and/or contractures
- Hyperpigmentation
- Limited range of motion with severe pain
- Peau d'orange
- Axillary cording
- Chest, trunk, and/or abdominal lymphedema

Early treatment is important. NCCN Guidelines² recommend proactive patient education in early stages while lymphedema symptoms are reversible, as well as education on ongoing symptom management.

Flexitouch Plus



Have a patient who may qualify for the Flexitouch Plus? Refer them today. Visit tactilemedical.com/order

*Not all of inclusive. TACTILE MEDICAL

Breast cancer Medicare criteria

Flexitouch Plus upper extremity documentation criteria for your Medicare/Medicare Advantage patients.

- 1 189.0 Lymphedema not elsewhere classified
197.2 Post-mastectomy lymphedema
- 2 Chest, trunk, and/or abdominal lymphedema
- 3 Thoroughly document all unique symptoms of severity (see front)
- 4 **Conservative therapy**
The conservative therapy trial must consist of the following treatments tried by the patient and assessed by a clinician in two office visits at least four weeks apart:
 - Compression and/or bandaging system, exercise, and elevation.
 - Minimum of two office visits with a clinician, at least four weeks apart, are required during the trial of conservative therapies.
 If patient is unable to comply with any component listed above, provide an explanation.
- 5 **Measurements**
Measurements must be taken by the clinician during an HCP and patient interaction. Note: It is best practice to document measurements of affected area(s) at every visit.
- 6 **Prognosis**
 - Symptom assessment: Assessment of symptoms after completion of conservative therapy for at least four weeks
 - Basic pump rule out: Reason why the patient would be prevented from receiving satisfactory treatment with use of a basic pump
 - The reason the advanced pump is necessary to improve functional status, relief of symptoms, and overall outcomes for the patient

Indications/contraindications: Indications, contraindications, warnings, and instructions for use can be found in our user guides at tactilemedical.com/our-lymphedema-solutions/ (lymphedema products).
Canadian Federal Health Care restricts these devices to be used by or on the order of a licensed healthcare practitioner.
Reference:
1. NCCN. NCCN Guidelines for Breast Cancer Treatment. *Keyhole Med*. 2018 Nov 15;7(20):1937-1944.
Photo permission on file at Tactile Medical.
Peau d'orange image: Williams A. Breast and trunk oedema after treatment for breast cancer. *J Lymphedema*. 2006;1(1).

Tactile Medical
1101 Mississippi Blvd, Suite 300
Minneapolis, MN 55416 USA
tactilemedical.com

Customer Care
Text or call 813.355.5100
Toll Free Phone: 813.374.7711 (813.362.2645)
Fax: 612.333.0101 / Toll Free Fax: 866.492.2649
Email: customerservice@tactilemedical.com
Hours: 7 am to 5:30 pm, CT Monday-Friday


Tactile Medical and Flexitouch are registered trademarks of Tactile Medical. ©2024 Tactile Medical. All rights reserved. 704636-001 Rev. 12/2024

Breast cancer-related lymphedema patient symptom screener.

CHECK ALL THAT APPLY

Arm symptoms	Trunk symptoms
<input type="checkbox"/> Arm swelling <input type="checkbox"/> Arm heaviness <input type="checkbox"/> Arm firmness <input type="checkbox"/> Increased arm temperature <input type="checkbox"/> Seroma formation (fluid buildup under the surface of the skin) <input type="checkbox"/> Arm tightness <input type="checkbox"/> Limited arm movement <input type="checkbox"/> Tingling in affected arm <input type="checkbox"/> Arm aching <input type="checkbox"/> Limited finger movement <input type="checkbox"/> Limited elbow movement <input type="checkbox"/> Limited wrist movement <input type="checkbox"/> Limited shoulder movement <input type="checkbox"/> Stiffness in the affected arm <input type="checkbox"/> Burning in the affected arm <input type="checkbox"/> Arm redness <input type="checkbox"/> Numbness in the affected arm <input type="checkbox"/> Tenderness in the affected arm <input type="checkbox"/> Pain in the affected arm	<p><i>Note: Differences in bra fit, including indentation at bands/straps or changes in band and cup size, are common indicators of truncal swelling.</i></p> <p>Breast, chest and collarbone area:</p> <input type="checkbox"/> Swelling or puffiness <input type="checkbox"/> Heaviness or fullness <input type="checkbox"/> Tightness or firmness <input type="checkbox"/> Dimpled hair follicles on breast; orange peel appearance
	<p>Side and axilla (armpit):</p> <input type="checkbox"/> Swelling or puffiness <input type="checkbox"/> Heaviness or fullness <input type="checkbox"/> Tightness or firmness <input type="checkbox"/> Feeling of a "ball" preventing arm from resting at side <input type="checkbox"/> Feeling of a cord pulling with motion
	<p>Shoulder and back:</p> <input type="checkbox"/> Swelling or puffiness <input type="checkbox"/> Heaviness or fullness <input type="checkbox"/> Tightness or firmness <input type="checkbox"/> Limited range of motion <input type="checkbox"/> Pain

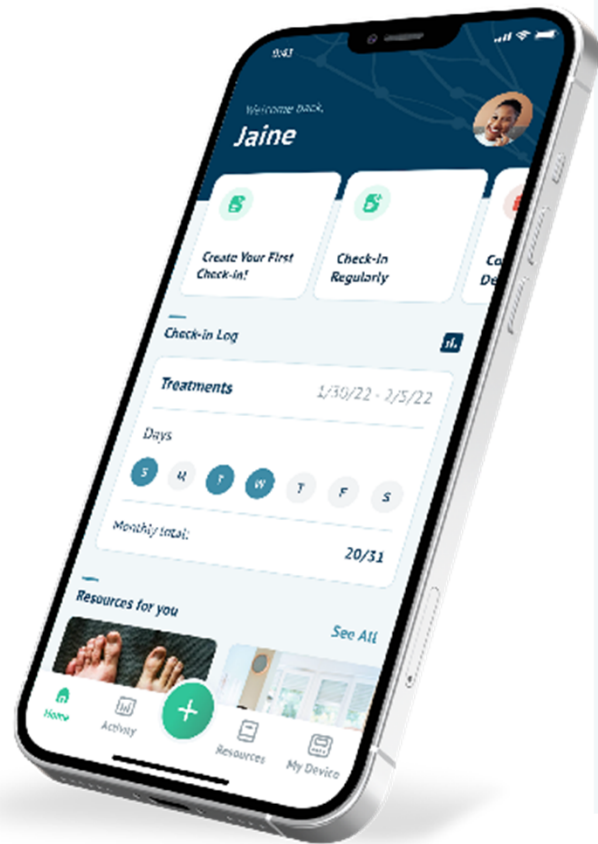
Kylee[®] is an easy-to-use, free mobile app to help you understand chronic swelling, track and manage your symptoms and live your best life! Download Kylee today!



TACTILE MEDICAL

Symptom screeners

Patients are active participants with Kylee



Create your daily Check-in

Today, May 27, 2025

Treatments

Add Compression Pump Treatments Add

Other Treatments Manage

Compression Garments	I did it! ✓
Manual Lymphatic Drainage	I did it! ✓
Exercise	I did it! ✓
Elevation	I did it! ✓



New breast cancer patient education videos

The screenshot displays the Tactile Medical website interface. At the top left is the Tactile Medical logo. The top right navigation bar includes links for 'Pay My Bill', 'Shop Accessories', 'Contact Us', and a search icon. Below this is a secondary navigation bar with 'Patients +', 'Clinicians +', 'Our Solutions +', 'Resource Hub +', and 'About Us +'. The main content area features two large promotional cards. The left card, titled 'SELF MANUAL LYMPHATIC DRAINAGE (MLD) GUIDES', includes a circular icon of hands and a dark blue footer with the text 'Self-manual lymphatic drainage (MLD) guides'. The right card, titled 'Breast cancer-related lymphedema video resources', features a collage of four images: a woman using a blue ball, a woman at a laptop, a woman in a blue blazer, and a woman with yellow dumbbells. It also includes a circular logo for 'Cancer Rehab PT', the text 'Oncology, Lymphedema, and Lymphatic Health Physical Therapy', and 'DR. KELLY STURM'. A small square button with an upward arrow is located at the bottom right of this card.

Tactile
MEDICAL

Pay My Bill Shop Accessories Contact Us Search 🔍

Patients + Clinicians + Our Solutions + Resource Hub + About Us +

SELF MANUAL LYMPHATIC DRAINAGE (MLD) GUIDES

Self-manual lymphatic drainage (MLD) guides

Breast cancer-related lymphedema video resources

Cancer Rehab
PT

Oncology,
Lymphedema, and
Lymphatic Health
Physical Therapy

DR. KELLY STURM

How to take action

Screen, stage, recommend

1. Screen

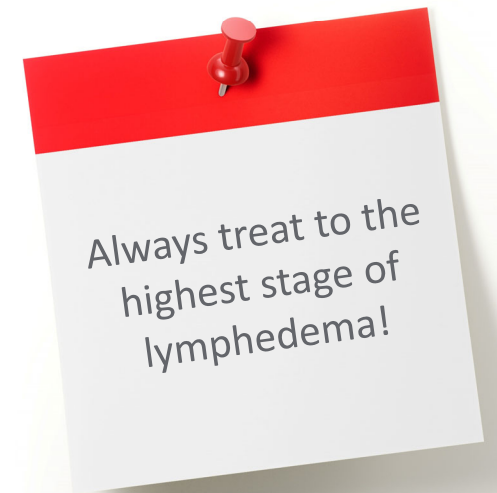- Limited range of motion⁶
- Skin firmness/thickening^{3,4}
- Pain or discomfort⁶
- Fullness/heaviness/swelling⁵
- Tightness or pulling with function¹
- Visible skin color change compared to unaffected side²

2. Stage

- **Stage 0:** Subclinical, subtle nonvisible changes including heaviness, aching
- **Stage 1:** Patient reports symptoms, transient swelling is responsive to elevation
- **Stage 2:** Onset of skin thickening and fibrosis even in the absence of swelling
- **Stage 3:** Chronic advanced skin changes, secondary skin disease


3. Recommend

- Based on clinical reasoning, symptoms are consistent with lymphedema
- Compression bra or tank top for static lymphatic support
- Pneumatic compression for dynamic lymphatic drainage



NCCN Guidelines Version 3.2023 – Survivorship – Lymphedema (www.nccn.org); The Breast Edema Enigma: Features, Diagnosis, Treatment, and Recommendations (S. Gupta, H. Mayrovitz, 4/2022); Lymphedema After Breast Cancer: Incidence, Risk Factors, and Effect on Upper Body Function (S C. Hayes, et al, 2007); Early surveillance is associated with less incidence and severity of breast cancer-related lymphedema compared with a traditional referral model of care; Lymphatic Pain in Breast Cancer Survivors (K Jones et al, Dec 2021); Do Patient-Reported Upper-Body Symptoms Predict Breast Cancer-Related Lymphoedema (Su Hayes SC, et al. 2022)

Revisiting the paradigm shift



Next steps

Utilize the 3-step “**screen, stage, recommend**” to identify appropriate candidates for lymphedema treatment with PCD

Your local Tactile Medical account manager will reach out via email to schedule a 30 min **learning lab** for live demonstration and review local insurance process

Tactile MEDICAL®

3701 Wayzata Blvd., Suite 300, Minneapolis, MN 55416 USA

T: 833.3TACTILE (833.382.2845) | F: 612.355.5101

705659 Rev A 5/2026

Flexitouch Plus system FDA indications for use and contraindications

Indications for use

The Flexitouch Plus system provides adjustable, gradient, sequential compression therapy for

- Primary and secondary lymphedema
- Phlebolymphe­dema
- Lipedema
- Venous insufficiencies
- Reducing wound healing time
- Treatment and assistance in healing stasis dermatitis, venous stasis ulcers, or arterial and diabetic leg ulcers
- Post mastectomy edema
- Edema following trauma and sports injuries
- Post immobilization edema

Contraindications

Contraindications include

- Heart failure (acute pulmonary edema, decompensated acute heart failure)
- Acute venous disease (acute thrombophlebitis, acute deep vein thrombosis, acute pulmonary embolism)
- Severe peripheral artery disease (critical limb ischemia including ischemic rest pain, arterial wounds or gangrene)
- Active skin infection/inflammatory disease (acute cellulitis, other uncontrolled skin or untreated inflammatory skin disease)
- Any circumstance where increased lymphatic or venous return is undesirable
- During pregnancy (applies to Flexitouch Plus trunk accessory)

Complete Flexitouch plus instructions for use are available in the system user guide, or at [Tactilemedical.com](https://www.tactilemedical.com)

References

- American Cancer Society. Cancer Facts & Figures 2024. Atlanta: American Cancer Society; 2024. Cancer statistics. SEER. Retrieved November 1, 2024 from <https://seer.cancer.gov/statistics/>
- American Cancer Society: Breast Cancer Risk and Prevention (<https://www.cancer.org/cancer/types/breast-cancer/risk-and-prevention/breast-cancer-risk-factors-you-cannot-change.html>)
- NCCN Clinical Practice Guidelines in Oncology, Genetic/Familial High-Risk Assessment, version 2.2025
- NCCN Guidelines Version 2.2024 Breast Cancer Screening and Diagnosis
- American Cancer Society: Survival Rates for Breast Cancer (<https://www.cancer.org/cancer/types/breast-cancer/understanding-a-breast-cancer-diagnosis/breast-cancer-survival-rates.html>)
- Rosenberger LH, Ren Y, Thomas SM, Greenup RA, Fayanju OM, Hwang ES, Plichta JK. Axillary lymph node dissection in node-positive breast cancer: are ten nodes adequate and when is enough, enough? *Breast Cancer Res Treat.* 2020 Feb;179(3):661-670. doi: 10.1007/s10549-019-05500-9.
- Che Bakri NA, Kwasnicki RM, Khan N, Ghandour O, Lee A, Grant Y, Dawidziuk A, Darzi A, Ashrafian H, Leff DR. Impact of Axillary Lymph Node Dissection and Sentinel Lymph Node Biopsy on Upper Limb Morbidity in Breast Cancer Patients: A Systematic Review and Meta-Analysis. *Ann Surg.* 2023 Apr 1;277(4):572-580. doi: 10.1097/SLA.0000000000005671.
- Ridner SH, Dietrich MS, Niermann K, Cmelak A, Mannion K, Murphy B. A Prospective Study of the Lymphedema and Fibrosis Continuum in Patients with Head and Neck Cancer. *Lymphat Res Biol.* 2016 Dec;14(4):198-205.

References (2)

- Chaput G, Ibrahim M, Towers A. Cancer-related lymphedema: clinical pearls for providers. *Curr Oncol*. 2020;27(6):336-340.
- Allam, O. et al. The impact of radiation on lymphedema: a review of the literature. Division of Plastic and Reconstructive Surgery, Yale University, New Haven, CT, USA . Dec 24, 2019
- Johnson AR, Granoff MD, Lee BT, Padera TP, Bouta EM, Singhal D. The Impact of Taxane-based Chemotherapy on the Lymphatic System. *Ann Plast Surg*. 2019;82(4S Suppl 3):S173-S178. doi:10.1097/SAP.0000000000001884
- Lee KT, Mun GH, Lim SY, Pyon JK, Oh KS, Bang SI. The impact of immediate breast reconstruction on post-mastectomy lymphedema in patients undergoing modified radical mastectomy. *Breast*. 2013 Feb;22(1):53-7.
- Zou L, Liu FH, Shen PP, Hu Y, Liu XQ, Xu YY, Pen QL, Wang B, Zhu YQ, Tian Y. The incidence and risk factors of related lymphedema for breast cancer survivors post-operation: a 2-year follow-up prospective cohort study. *Breast Cancer*. 2018 May;25(3):309-314.
- McDuff SGR, Mina AI, Brunelle CL, et al. Timing of Lymphedema After Treatment for Breast Cancer: When Are Patients Most At Risk?. *Int J Radiat Oncol Biol Phys*. 2019;103(1):62-70.
- Executive Committee of the International Society of Lymphology. The diagnosis and treatment of peripheral lymphedema: 2020 Consensus Document of the International Society of Lymphology. *Lymphology*. 2020;53(1):3-19.

References (3)

- Fu MR, Axelrod D, Cleland CM, et al. Symptom report in detecting breast cancer-related lymphedema. *Breast Cancer* (Dove Med Press). 2015;7:345–352.
- Sun, F., Skolny, M.N., Swaroop, M.N. et al. The need for preoperative baseline arm measurement to accurately quantify breast cancer-related lymphedema. *Breast Cancer Res Treat* 157, 229–240 (2016).
- Bundred, N., Foden, P., Todd, C. et al. Increases in arm volume predict lymphoedema and quality of life deficits after axillary surgery: a prospective cohort study. *Br J Cancer* 123, 17–25 (2020)
- Koehler LA, Mayrovitz HN. Tissue Dielectric Constant Measures in Women With and Without Clinical Trunk Lymphedema Following Breast Cancer Surgery: A 78-Week Longitudinal Study. *Phys Ther.* 2020.
- Mazor M, Smoot BJ, Mastick J, et al. Assessment of local tissue water in the arms and trunk of breast cancer survivors with and without upper extremity lymphoedema. *Clin Physiol Funct Imaging.* 2019;39(1):57–64.
- Degnim AC, Miller J, Hoskin TL, Boughey JC, Loprinzi M, Thomsen K, Maloney S, Baddour LM, Cheville AL. A prospective study of breast lymphedema: frequency, symptoms, and quality of life. *Breast Cancer Res Treat.* 2012;134(3):915-922. doi: 10.1007/s10549-012-2004-x.
- Aldrich MB, Rasmussen JC, DeSnyder SM, Woodward WA, Chan W, Sevick-Muraca EM, Mittendorf EA, Smith BD, Stauder MC, Strom EA, Perkins GH, Hoffman KE, Mitchell MP, Barcenas CH, Isales LE, Shaitelman SF. Prediction of breast cancer-related lymphedema by dermal backflow detected with near-infrared fluorescence lymphatic imaging. *Breast Cancer Res Treat.* 2022 Aug;195(1):33-41.
- Bundred N, Foden P, Todd C, et al. Increases in arm volume predict lymphoedema and quality of life deficits after axillary surgery: A prospective coho. *Br J Cancer.* 2020;123(1):17-25.

References (4)

- Nguyen TT, Hoskin TL, Habermann EB, Cheville AL, Boughey JC. Breast Cancer-Related Lymphedema Risk is Related to Multidisciplinary Treatment and Not Surgery Alone: Results from a Large Cohort Study. *Ann Surg Oncol*. 2017 Oct;24(10):2972-2980.
- Rockson SG. Lymphedema after breast cancer treatment. *N Engl J Med*. 2018;379(20):1937-1944.
- Koelmeyer LA, Gaitatzis K, Dietrich MS, Shah CS, Boyages J, McLaughlin SA, Taback B, Stollendorf DP, Elder E, Hughes TM, French JR, Ngui N, Hsu JM, Moore A, Ridner SH. Risk factors for breast cancer-related lymphedema in patients undergoing 3 years of prospective surveillance with intervention. *Cancer*. 2022 Sep 15;128(18):3408-3415. doi: 10.1002/cncr.34377. Epub 2022 Jul 7. PMID: 35797441.
- Miller CL, Colwell AS, Horick N, et al. Immediate Implant Reconstruction Is Associated With a Reduced Risk of Lymphedema Compared to Mastectomy Alone: A Prospective Cohort Study. *Ann Surg*. 2016;263(2):399-405.
- Kim JS, Kim JH, Chang JH, Kim DW, Shin KH. Prediction of breast cancer-related lymphedema risk after postoperative radiotherapy via multivariable logistic regression analysis. *Front Oncol*. 2022 Oct 26;12:1026043
- Bains SK, Stanton AW, Cintolesi V, Ballinger J, Allen S, Zammit C, Levick JR, Mortimer PS, Peters AM, Purushotham AD. A constitutional predisposition to breast cancer-related lymphoedema and effect of axillary lymph node surgery on forearm muscle lymph flow. *Breast*. 2015 Feb;24(1):68-74
- Brunelle CL, Roberts SA, Shui AM, Gillespie TC, Daniell KM, Naoum GE, Taghian A. Patients who report cording after breast cancer surgery are at higher risk of lymphedema: Results from a large prospective screening cohort. *J Surg Oncol*. 2020 Aug;122(2):155-163.
- Montagna G, Zhang J, Sevilimedu V, et al. Risk Factors and Racial and Ethnic Disparities in Patients With Breast Cancer–Related Lymphedema. *JAMA Oncol*. 2022;8(8):1195–1200. doi:10.1001/jamaoncol.2022.1628

References (5)

- Daniell KM, Bardia A, Sun F, Roberts SA, Brunelle CL, Gillespie TC, Sayegh HE, Naoum GE, Juric D, Isakoff SJ, Fitzgerald DM, Taghian AG. Incidence of peripheral edema in patients receiving PI3K/mTOR/CDK4/6 inhibitors for metastatic breast cancer. *Breast Cancer Res Treat.* 2019 Jun;175(3):649-658. doi: 10.1007/s10549-019-05206-y.
- Hayes SC, Dunn M, Plinsinga ML, Reul-Hirche H, Ren Y, Laakso EL, Troester MA. Do Patient-Reported Upper-Body Symptoms Predict Breast Cancer-Related Lymphoedema: Results from a Population-Based, Longitudinal Breast Cancer Cohort Study. *Cancers (Basel).* 2022 Dec 5;14(23):5998.
- Shah, C., Zambelli-Weiner, A., Delgado, N. et al. The impact of monitoring techniques on progression to chronic breast cancer-related lymphedema: a meta-analysis comparing bioimpedance spectroscopy versus circumferential measurements. *Breast Cancer Res Treat* 185, 709–740 (2021)
- Rafn BS, Christensen J, Larsen A, Bloomquist K. Prospective Surveillance for Breast Cancer-Related Arm Lymphedema: A Systematic Review and Meta-Analysis [published online ahead of print, 2022 Jan 25]. *J Clin Oncol.* 2022;JCO2101681. doi:10.1200/JCO.21.01681
- Suami H, Heydon-White A, Mackie H, Czerniec S, Koelmeyer L, Boyages J. A new indocyanine green fluorescence lymphography protocol for identification of the lymphatic drainage pathway for patients with breast cancer-related lymphoedema. *BMC Cancer.* 2019 Oct 22;19(1):985.
- Mehta M, Moroni E, Fishman J, De La Cruz C. D25. Alternative Patterns of Superficial Lymphatic Drainage in the Breast and Trunk after Breast Cancer Surgery. *Plast Reconstr Surg Glob Open.* 2023 Apr 26;11(4 Suppl):74. doi: 10.1097/01.GOX.0000934712.36562.77.
- Adams, K.E. et al. (2010) Direct Evidence of Lymphatic Function Improvement After Advanced Pneumatic Compression Device Treatment of Lymphedema. *Biomed Opt. Express.* 2010 Jul15; 1(1): 114-125.

References (6)

- Karaca-Mandic, P. et al. (2015) The Cutaneous, Net Clinical, and Health Economic Benefits of Advanced Pneumatic Compression Devices in Patients with Lymphedema. *JAMA – Dermatology*, Oct. 2015.
- Wilburn O, Wilburn P, Rockson SG. A pilot, prospective evaluation of a novel alternative for maintenance therapy of breast cancer-associated lymphedema [ISRCTN76522412]. *BMC Cancer*. 2006 Mar 29;6:84. doi: 10.1186/1471-2407-6-84.
- Maingi S, O'Malley EM. Impact of text reminders on pneumatic compression device (PCD) compliance in patients with breast cancer-related lymphedema. *Support Care Cancer*. 2023 Dec 16;32(1):33. doi: 10.1007/s00520-023-08246-9.
- Bowman, C., Rockson, S.G. The lymphedema patient experience within the healthcare system: a cross-sectional epidemiologic assessment. *Sci Rep* 14, 12600 (2024). <https://doi.org/10.1038/s41598-024-63145-1>